

# Mercury Poisoning: A Clinical and Toxicological Perspective



José A. Centeno

U.S. Armed Forces Institute of Pathology

Email: [centeno@afip.osd.mil](mailto:centeno@afip.osd.mil)

# Man and Mercury

“A man and a woman  
in a mercury bath”

Philipp Morgenstern  
Basel, In Verlegung Ludwig  
Königs, 1613 Turba  
philosophorum; das ist, Das  
Buch von der güldenen Kunst



*National Library of Medicine  
History of Medicine Division  
<http://www.nlm.nih.gov/>*

# Mercury (Hg)

Speciation (chemical/physical forms) of Hg:

- elemental ( $\text{Hg}^0$ )
- inorganic (mercurous,  $\text{Hg}^{1+}$  or mercuric,  $\text{Hg}^{2+}$ )
- organic (methyl-, ethyl-, or phenylmercury)

# Elemental Mercury ( $\text{Hg}^0$ )

## Sources:

### Liquid form

- medical and environmental measuring devices
- disc batteries
- fluorescent light bulbs
- dental amalgam

### Vapor form

- burning fossil fuels
- manufacturing, processing, and mining

Chemical Characteristics: High vapor pressure at 20°C

maximum industrial allowance = 0.1 mg/m<sup>3</sup>;

CDC-ATSDR minimal risk level = 0.2 ug/m<sup>3</sup> in a 10-ft<sup>2</sup>

# Elemental Mercury ( $\text{Hg}^0$ )

## Exposure Pathways:

Respiratory (harmful vapors inhaled)

- easily absorbed into bloodstream
- easily crosses blood-brain barrier  
oxidizes and deposits in nervous system

Placenta

- easily passes through placenta, accumulating in fetus

Skin

- minimally absorbed through intact skin

Gastrointestinal

- minimally absorbed through gut

# Elemental Mercury ( $\text{Hg}^0$ )

## Clinical Manifestations:

### Lungs (acute inhalation)

- pneumonitis
- respiratory failure

### Kidney is final target organ

- mercury accumulates as body tries to clear toxin

### Significant prolonged or acute exposure

- salivation
- sweating
- mouth ulcers
- erethism

red palms/soles

emotional lability

memory impairment

# Case Presentation

## **Mercury experiment leads to apartment house evacuation Teen heats substance creating hazardous vapor**

*Gaithersburg, MD--* A teen-ager who took mercury out of a thermometer and heated it exposed his family and neighbors to a potential carcinogen today, police said... "In the apartment we did find high levels, and ... the vapor is what we're concerned about," ... Five people from the apartment were evaluated at a hospital, where two had trouble breathing. Investigators said that they were led to the apartment building Thursday afternoon after the boy brought some of the mercury to school and spilled it.

**The Associated Press Copyright © 2002, Originally published April 11, 2002,  
7:18 PM EDT**



# Washington Post

## August 2003

- 0.5 – 2.0 g Hg was spilled
- School was closed for ~1 month
- Community screening and counseling
- Total cost ~\$1.5 Million



Principal Art Bridges, right, prepares for today with EPA's Marcos Aquino.

## Ballou Students Undergo Mercury Screening Today

BALLOU. From B1

Agency officials plan to use sensors that can detect the vapors from mercury in a matter of seconds, without damaging clothing.

After the testing, ninth-graders are to go to Hart in buses, and students in grades 10 through 12 are to take buses to the old convention center. Officials said parents should not take students directly to those sites because only those who have been screened and transported by school bus will be allowed entry.

Ballou has 1,300 students, although only about 900 were in attendance when the school was evacuated Thursday, officials said.

Classes today will be limited, but school officials anticipate having

enough materials to run full-fledged classes in all areas by tomorrow, said Principal Art Bridges. They are photocopying instructional material and may lend surplus books stored in warehouses to students who left their books in the school Thursday.

Bridges said the cleanup could take a month or more, depending on the extent of the contamination, though playing fields at the school have already been cleared for use. Extracurricular activities are scheduled to resume this week.

"Ballou's students' education will not be compromised," he said.

Officials reported no progress in the investigation into Thursday's incident, and they declined to estimate a cost for the cleanup and related disruptions. The mercury was spilled in the gymnasium, cafeteria, hallways and several classrooms. Superintendent Paul L. Vance said the system may eventually seek financial help.

Officials repeatedly urged whoever



# Mercury (Hg)

## Speciation:

- elemental ( $\text{Hg}^0$ )
- inorganic (mercurous,  $\text{Hg}^{1+}$  or mercuric,  $\text{Hg}^{2+}$ )
- organic (methyl-, ethyl-, or phenylmercury)

# Inorganic Mercury ( $\text{Hg}^{1+}$ and $\text{Hg}^{2+}$ )

## Sources:

Inorganic mercury salts

mercurous (monovalent)  
and mercuric (divalent)

disinfectant

antibacterial

antiparasitic

cathartic

diuretic

Mercurous chloride  
(calomel)

teething powder, cholera

## Exposure Pathways

Gastrointestinal

- local irritant
- can be very caustic
- little systemic absorption  
unless the protective  
barrier compromised

Skin

- poor systemic absorption  
unless exposed to  
large amounts

# Inorganic Mercury ( $\text{Hg}^{1+}$ and $\text{Hg}^{2+}$ )

## Clinical Manifestations:

Caustic nature can break down skin or mucosa, leading to

- kidney damage
- neurological damage

Prolonged exposure may cause

- peripheral neuropathy
- hypersensitivity reactions on skin or in kidney
- salivation
- sweating
- erethism

# Pink Disease

First written description of Pink disease was by a German physician, Selter, in 1903.

Thought to be infectious...

1903 Selter (Germany)

1914 Swift (Australia) Swift's disease

1920 Clubb (Australia) Pink disease

1920 Weston (Columbia) Acrodynia

1922 Feer (Zurich) Feer's disease

Chronic Mutilating Acrodynia (Weber).  
Paroxysmal Acrodynia of Infancy (Bézy).  
Acro-erythroedema (Caillard & Terrain).  
Dermato-polyneuritis (Thursfield).  
Erythroedema (Swift).  
Australian erythroedema (Comby).  
Erythroedema polyneuritis (Braithwaite & Pegge).  
Feer's disease (Bruckner, Bohe).  
Swift-Feer's disease (Jenny).  
Neurosis of Feer (Erickson).  
Neurosis of the vegetative system (Feer, Tacilazic, Weitprecht, Deuber).  
Pink disease (Clubb).  
A syndrome characterised by insomnia, sweating and peripheral vasomotor phenomena (Janet & Dyras).  
A syndrome of childhood consisting of pathological changes in the psychology and the vegetative nervous system (Haushalter, Hoeschstetter).  
A polyneuritic syndrome resembling pellagra (Byfield).  
A syndrome of sweating with paroxysmal attacks of pain (Nobécourt & Pichon).  
Trophodermatoneurose (Selter).

*Rocaz, L'infantile Acrodynie, 1931*

# Pink Disease

## Manifestations:

- develops in young children
- an “anguished” expression, and progressive loss of speech, hallucinations, and delirium.
- profuse sweating
- red, peeling skin
- swollen, clammy, and cold hands and feet
- intense itching
- hair loss

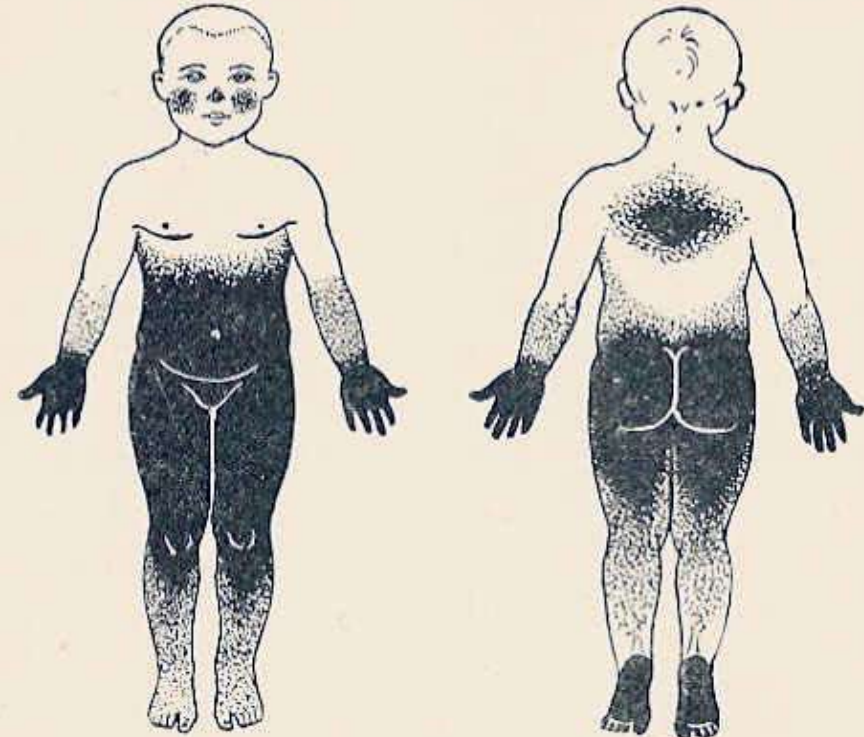


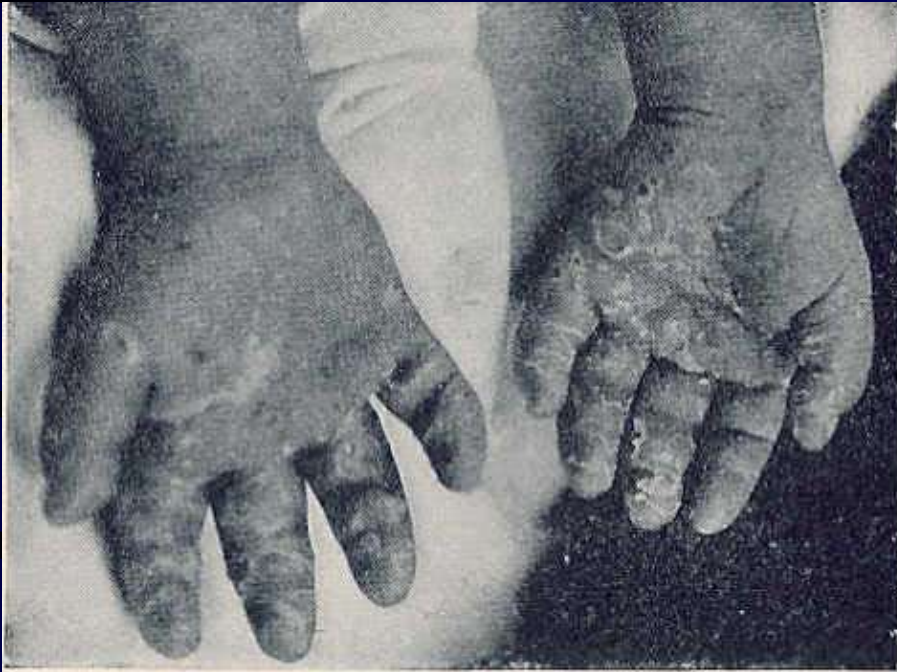FIG. 15.

The distribution and intensity of the erythematous rash in a child aged 2 years. The colour varied from a bright pink to dark red. (Ch. Rocaz.)

*Rocaz, L'infantile Acrodynie, 1931*



# Pink Disease



FIGS. 10 and 10A.

The hands of a child with pink disease. Note the sausage-shaped fingers and the desquamation. (Patient of MM. Bosc and Lafay.)

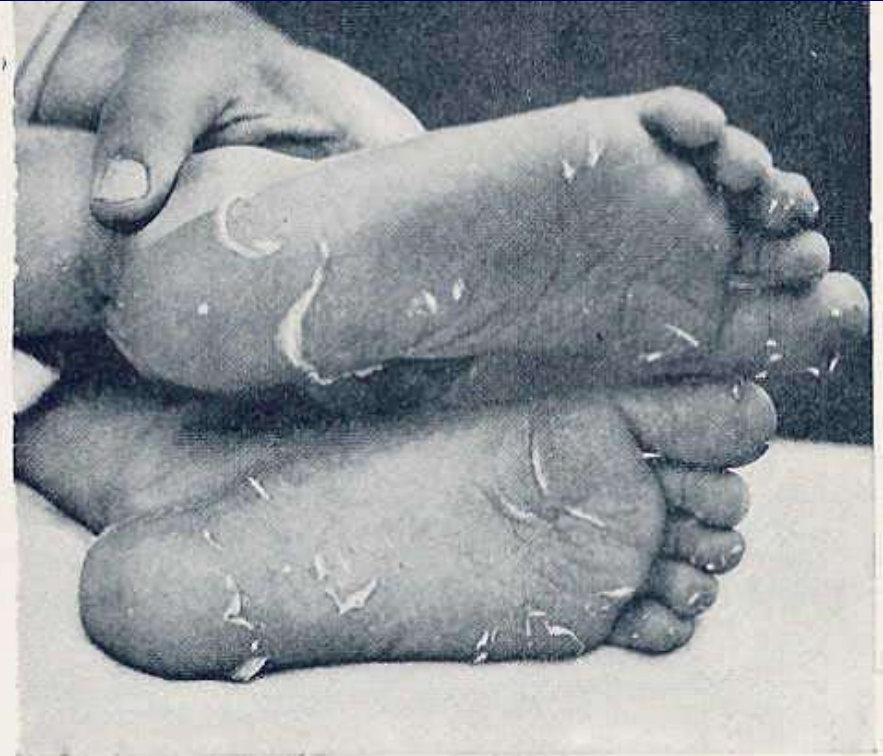

FIG. 14.

Desquamation on the soles of the feet in a case of pink disease aged  $3\frac{1}{2}$  years. (Ch. Rocaz.)

*Rocaz, L'infantile Acrodynie, 1931*

# Acrodynia

## Derivation

### Latin root

*acr-* “*extremity*” + *odynia-* “*pain*” =  
*acrodynia* = *painful extremities*



# Acrodynia

## Signs and Symptoms:

- Painful hands and feet
- Pink (dusky progression) color to hands and feet that fade at ankles/wrists
- Nose and cheeks have scarlet hue
- Profuse sweating
- Profuse salivation
- **Photophobia**
- **Hypotonia**
- Muscle wasting and loss of deep tendon reflexes
- Lethargy, apathy, irritability

# Acrodynia

“At the same time subjective sensations of pain, heat and tingling, especially in the hands and feet.”

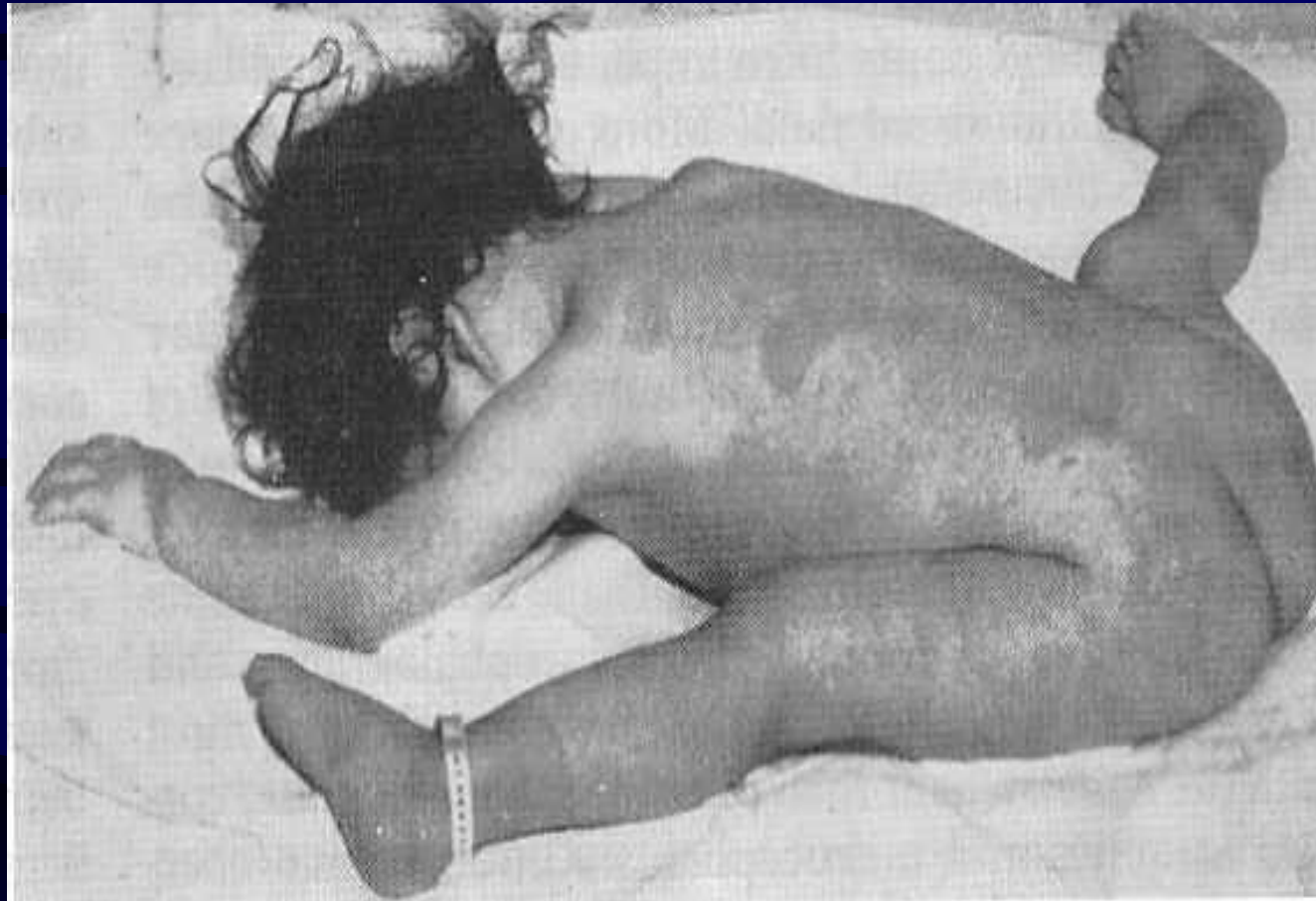

FIG. 4.

A child with pink disease soaking her hands in cold water in an attempt to quell the intense burning sensations. (A patient of MM. Bosc and Lafay.)

*Rocaz, L'infantile Acrodynie, 1931*

# Acrodynia



Child with remarkable hypotonia, burying her head to avoid light shining in her eyes.

Notice the characteristic rash.

*Nelson Textbook of Pediatrics*

# Mercury (Hg)

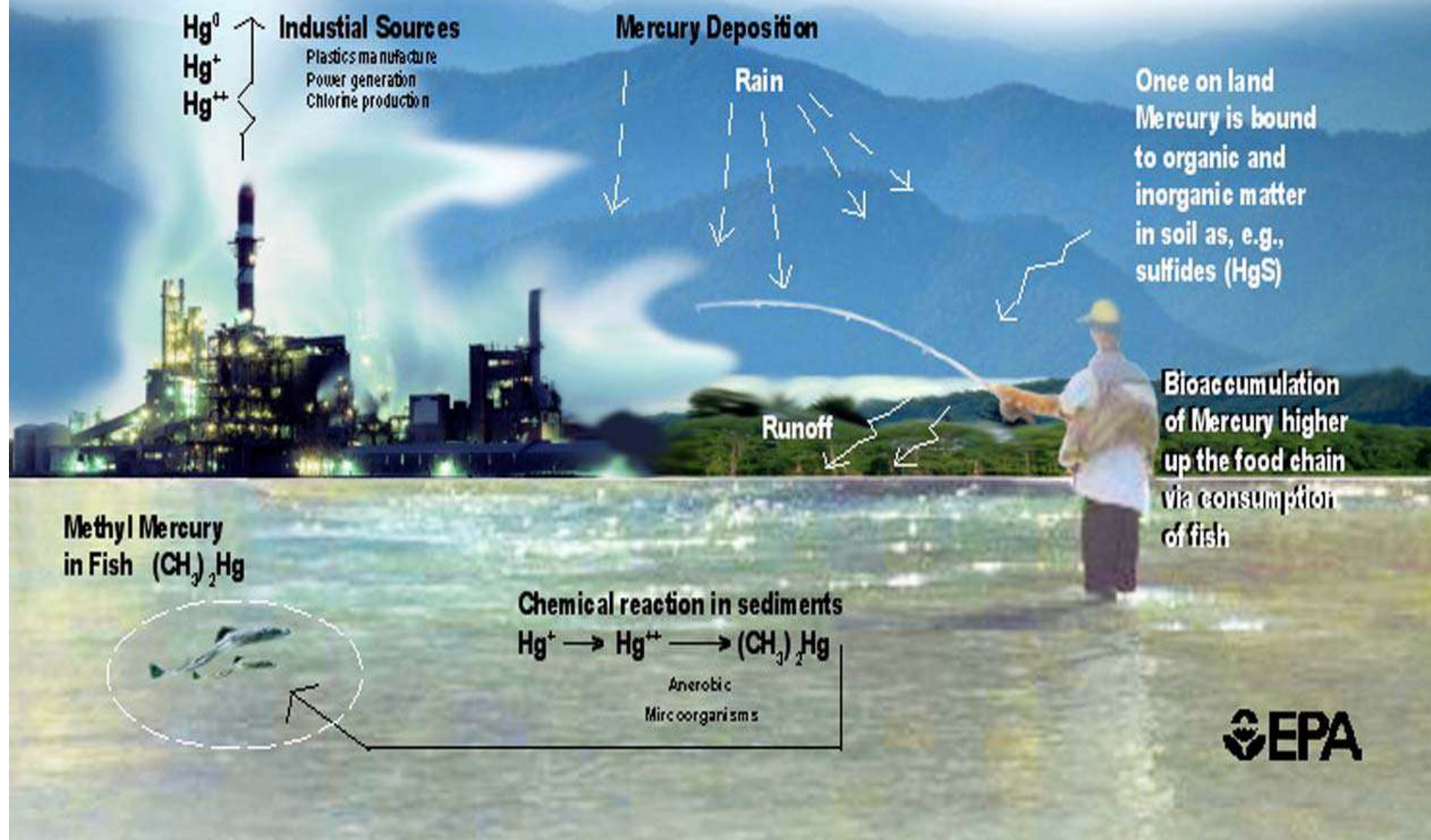
## Speciation:

- elemental ( $\text{Hg}^0$ )
- inorganic (mercurous,  $\text{Hg}^{1+}$  or mercuric,  $\text{Hg}^{2+}$ )
- organic (methyl-, ethyl-, or phenylmercury)



# Sources and Paths of Mercury in the Environment

## Sources & Paths of Mercury in the Environment



# Organic Mercury (methyl, ethyl, phenyl)

## Sources:

### Methylmercury

- used as a crop fungicide
- ubiquitous in environment since microorganisms methylate elemental mercury

### Ethylmercury

- thimerosal used as an antiseptic and vaccine preservative

### Phenylmercury

- fungicide in latex paints

# Thimerosal (merthiolate)

## Sources:

Vaccine preservative, nasal spray, contact eye solutions.

## Health Effects:

- Exposure to Hg in utero and children may cause mild to severe mental retardation and mild to severe motor coordination impairment;
- Autism?
- Dementia?

## Treatment:

- methyl-B12, ointment DMPS/glutathione (GSH).



# Organic Mercury (methyl, ethyl, phenyl)

## Exposure Pathways

### Gastrointestinal

- almost completely absorbed in gut because of lipid solubility

### Nervous System

- easily crosses blood-brain barrier
- has affinity for certain nervous system cells (methyl)

### Placenta

- easily crosses placenta, entering fetal circulation

### Breast Milk

- easily accumulates and transferred in milk

### Respiratory

- unstable phenyl-mercury bond can result in the inhalation of elemental mercury

# Organic Mercury (methyl, ethyl, phenyl)

## Clinical Manifestations:

Neurological signs and symptoms most prominent

- weakness
- paresthesia
- visual and auditory deficits
- tremor
- coma

Children and fetuses exceptionally vulnerable

- seizures
- psychomotor retardation
- visual and auditory impairment

# Historical Cases of Methyl-Hg Poisoning

- Known cases of Dimethylmercury Poisoning:
  - 1865 (England) - during synthesis (2 chemists)
  - 1943 (Canada) - leaking vial in warehouse
  - 1974 (Czechoslovakia) - inadequate protection
  - 1997 (USA) - diMeHg used as NMR standard

**“Great Shock”  
The June 1997  
death of Karen  
Wetterhahn from  
an accident that  
had occurred  
months earlier  
stunned the  
scientific  
community**




Photo: *The Scientist* 11(21), 1997

# Case Report on DiMeHg Exposure

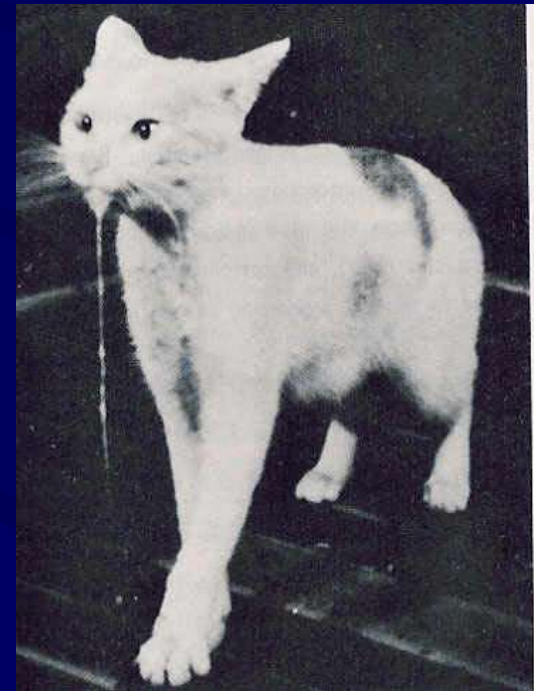
## *(Clinical Description)*

- 48-year old chemistry admitted to Dartmouth Med. Ctr (1/20/97)
- Reported exposure to (Me)<sub>2</sub>Hg on August 14, 1996
- Whole-blood Hg level was more than 1000 ug/L
- Chelation therapy (oral succimer, 10 mg/kg was begun on day 168
- Lab results: whole-blood Hg = 4000 ug/L (NR=1-8, toxic level>20); Urinary Hg=234 ug/L (NR 1-5, toxic level >50)
- Patient lapse into a coma (176 days after exposure): vegetative state
- Died on June 8, 1997 (298 days after exposure)

# Case Presentation

In the early 1950's, in a small, serene bay in Kyushu, Japan...

- fish were found floating in the sea
- crows would fall out of the sky
- cats would have unexplained “fits”
  - convulsions
  - running in circles
  - somersaulting
  - excessive salivating
  - jumping into the sea
  - and drowning





# Minamata Disease

Organic Mercury Poisoning  
Environmental Contamination

Minamata Bay, Japan (1956)

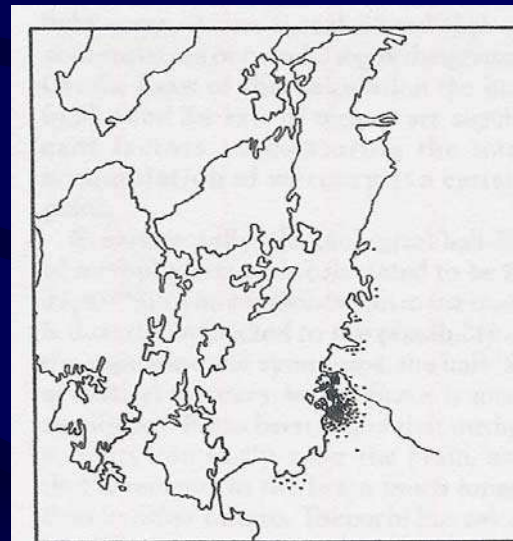
Iraq (1956, 1960, 1971)

Pakistan (1969)

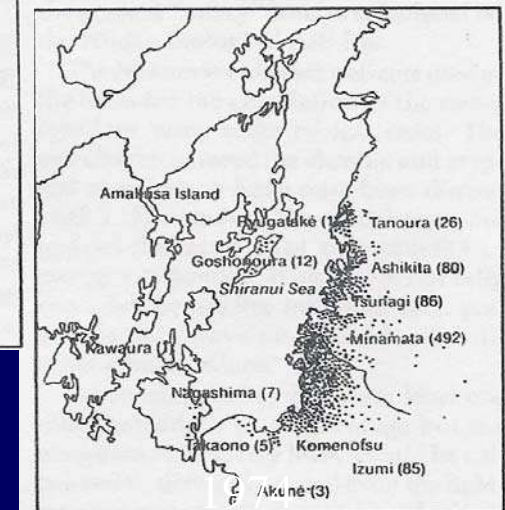
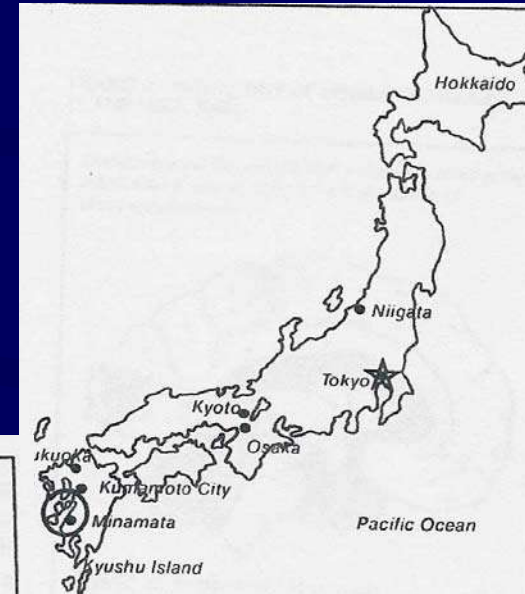
Guatemala (1963)

Japan (1964)

Ghana (1967)



1962



Minamata, W. Eugene and Aileen Smith



# Minamata Disease

## Different Forms of Minamata Disease

- Congenital
- Infantile
- Adult

Remarkable affinity for:

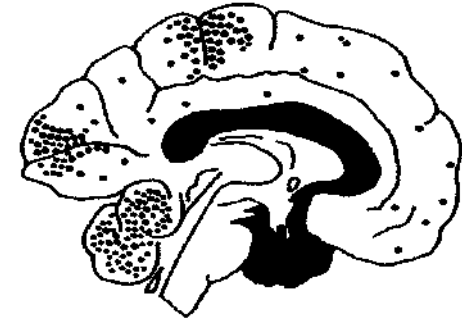
cerebellum

frontal lobe precentral cortex

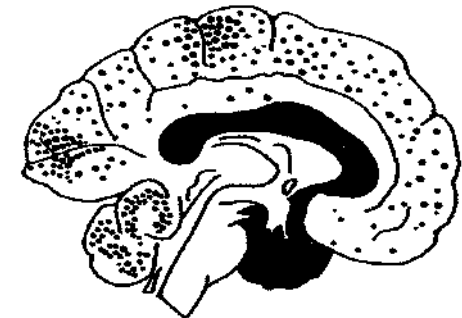
parietal lobe postcentral cortex

occipital lobe calcarine cortex

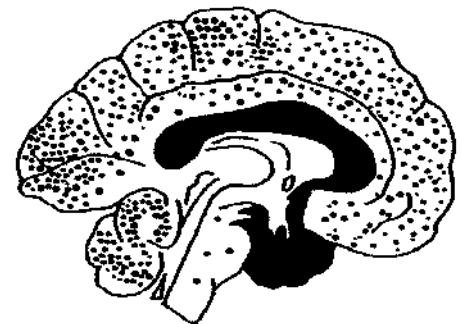
Comparison of the distribution of lesions among the adult, infant, and congenital infant victims of Minamata Disease.



*Adult Minamata Disease*



*Non-congenital infantile Minamata Disease*



*Congenital Minamata Disease*

# Minamata Disease

## Congenital:

Developmental delay

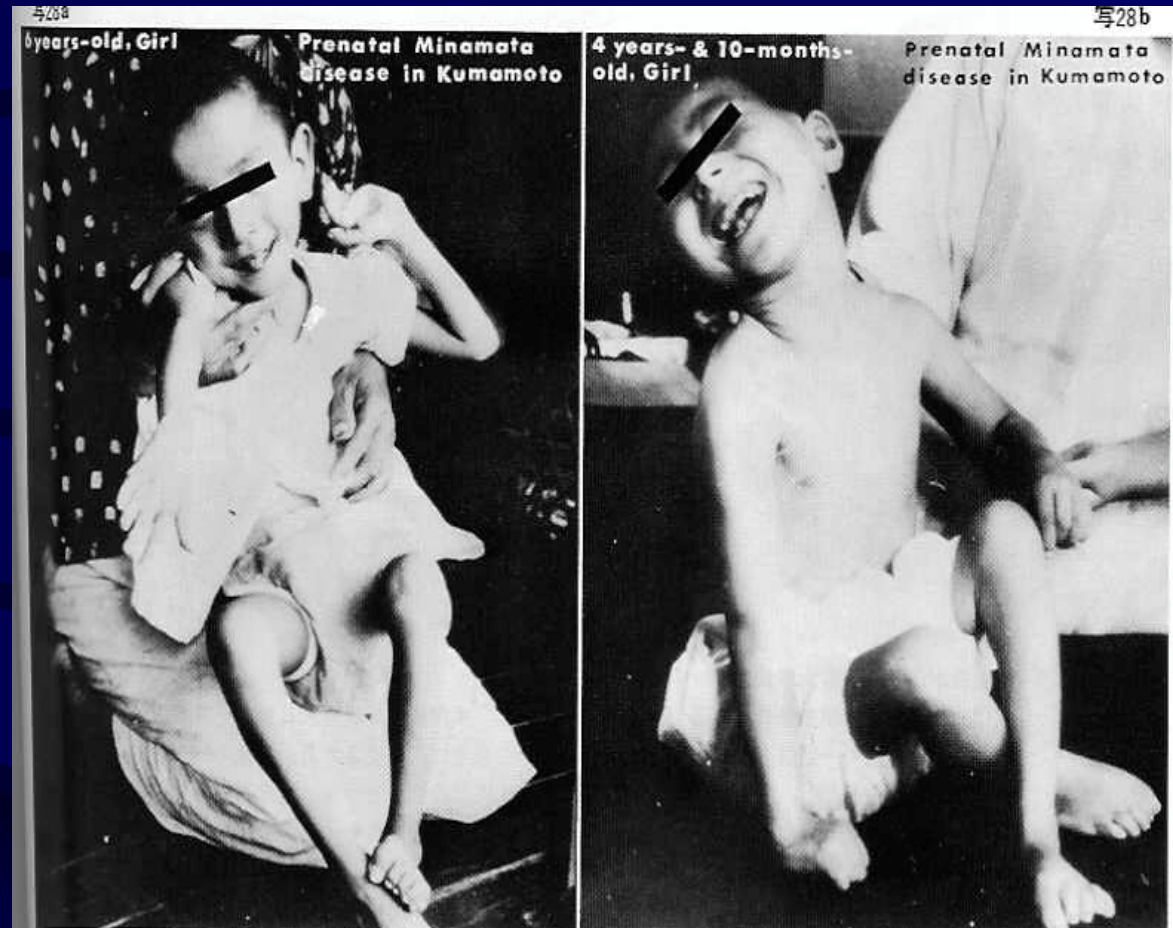
- mental
- physical

Blindness

Deafness

Muscle atrophy

Seizures



*Minamata*, W. Eugene and Aileen Smith

# Minamata Disease

## Acquired

Numbness of extremities

Lack of coordination

hands

gait

speech

Weakness

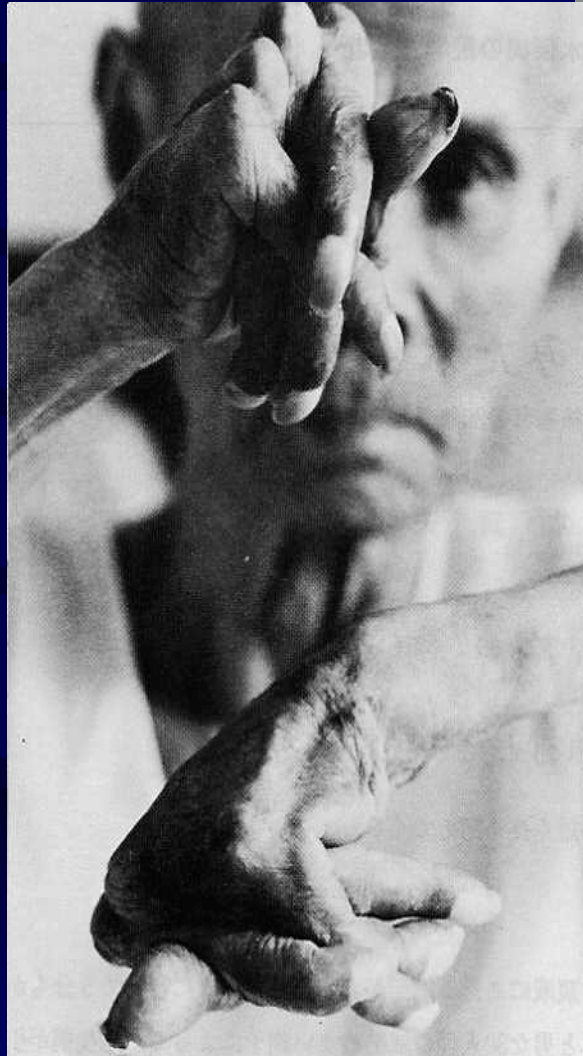
Sensory loss

touch

vision

hearing

Seizures



*Minamata, W. Eugene and Aileen Smith*

# Solutions

## *(Treatment Summary)*

Chelation therapy is the standard intervention for elemental and inorganic poisoning (eg. BAL, DMPS, EDTA, vitamin C)

However, chelating agents may increase the CNS organic mercury concentration.

Chelating agents increase the mercury excretion.


However, there is little evidence to show that chelation arrests or decreases the toxic effects of chronic mercury poisoning.

Indications for chelation are not well established.

However, chelation is often used empirically in severe acute cases.

# Man and Mercury: Learning for the Future

Neither treatment nor  
tragedy need occur if  
prevention prevails...



*Minamata*, W. Eugene and Aileen Smith