


Mercury Poisoning: A Clinical Toxicological and Medical Geology Perspective



José A. Centeno

U.S. Armed Forces Institute of Pathology

Email: centeno@afip.osd.mil

Mercury and Dental Amalgams

Should we be concerned?



Int. J. Hyg. Environ. Health 207 (2004); 391–397
<http://www.elsevier.de/intjhyg>

International Journal
of Hygiene and
Environmental Health

Scientific Comment

Amalgam studies: Disregarding basic principles of mercury toxicity

J. Mutter^a, J. Naumann^a, C. Sadaghiani^a, H. Walach^a, G. Drasch^b

^a Institute for Environmental Medicine and Hospital Epidemiology, University Hospital, Freiburg, Germany

^b Institute of Forensic Medicine, Ludwig-Maximilians-University, Munich, Germany

Received April 11, 2003 · Revision received February 2, 2004 · Accepted February 6, 2004

Abstract

Dental amalgam, which has been used for over 150 years in dental practice, consists of about 50% metallic mercury. Studies on animal and humans show that mercury is continuously released from dental amalgam and absorbed by several body tissues. It is widely accepted that the main source of mercury vapor is dental amalgam and it contributes substantially to mercury load in human body tissues. There is still a controversy about the consequences of this additional mercury exposure from amalgam to human health. Many studies were performed to evaluate possible adverse effects. In this comment, these studies were analyzed with regard to their methodical quality by considering the newest findings on mercury toxicity and metabolism. In sum, a number of studies are methodically flawed drawing inaccurate conclusions as to the safety of dental amalgam.

Key words: Dental amalgam – mercury – toxicity – adverse effects

Medical Geology and Exposure to Mercury

Research Studies

Mercury exposure and malaria prevalence among gold miners in Pará, Brazil

Exposição a mercúrio e prevalência de malária entre
garimpeiros de ouro do Pará, Brasil

Ellen K. Silbergeld¹, Denis Nash², Circey Trevant¹, G. Thomas Strickland²,
Jose Maria de Souza³ and Rui S.U. da Silva³


Abstract *Economic development, including resource extraction, can cause toxic exposures that interact with endemic infectious diseases. Mercury is an immunotoxic metal used in the amalgamation of gold, resulting in both occupational exposures and environmental pollution. A cross-sectional medical survey was conducted in 1997 on 135 garimpeiros in Para, Brazil, because of their risks of both mercury exposure and malaria transmission. Mean levels of blood and urine mercury were well above non-exposed background levels. Twenty-six subjects had malaria parasitemia: Health symptoms consistent with mercury exposure were reported, but neither symptoms nor signs correlated with mercury levels in blood or urine. We did not find a dose response relationship between mercury exposure and likelihood of prevalent malaria infection, but there was a possible reduction in acquisition of immunity that may be associated with conditions in gold mining, including mercury exposure.*

Key-words: *Mercury. Garimpagem. Malaria. Toxicity.*

“Garimperos” and Gold Mining in Brazil



Courtesy: Prof. Bernardino Figueredo, Univ. of Campinas, Brazil

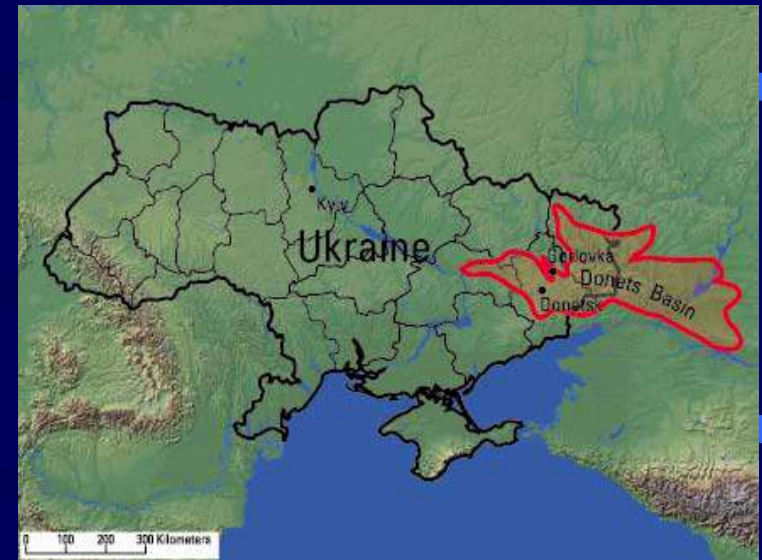



Mercury in Gorlovka

(Kolker A, Panov B, Kundiev Y, Gibb H, Centeno JA, in progress)

- Gorlovka (pop. 320,000), 50 km NE of Donetsk, adjacent to Nikitovka mercury mines, where byproduct coals have had the highest mercury contents in the region. Mercury sources include mine tailings and coal burning.
- Little or no available environmental or health information for Gorlovka residents.
- Previous study of children in two Gorlovka schools suggests high mercury contents in urine, blood, bones.



Mercury (Hg)


Speciation (chemical/physical forms) of Hg:

- elemental (Hg^0)
- inorganic (mercurous, Hg^{1+} or mercuric, Hg^{2+})
- organic (methyl-, ethyl-, or phenylmercury)

Primary Sources: dental amalgams, industrial emissions, pharmaceuticals, cosmetics, food (contaminated fish)

Sources and Paths of Mercury in the Environment

Sources & Paths of Mercury in the Environment



Health Risks from Mercury

- Exposure due to consumption of methyl-mercury in fish.
- Nervous system effects and developmental disorders. Documented effects of chronic exposure at low levels. Risk to fetuses and infants is greatest.
- Strong association with kidney damage and disease.
- Possible association with increased risks of lung cancer and cardiovascular disease.

Elemental Mercury (Hg^0)

Sources:

Liquid form

medical and environmental measuring devices

disc batteries

fluorescent light bulbs

dental amalgam

Vapor form

burning fossil fuels

manufacturing, processing, and mining

Chemical Characteristics: High vapor pressure at 20°C

maximum industrial allowance = 0.1 mg/m³;

CDC-ATSDR minimal risk level = 0.2 ug/m³ in a 10-ft²

Elemental Mercury (Hg^0)

Exposure Pathways:

Respiratory (harmful vapors inhaled)

- easily absorbed into bloodstream
- easily crosses blood-brain barrier
oxidizes and deposits in nervous system

Placenta

- easily passes through placenta, accumulating in fetus

Skin

- minimally absorbed through intact skin

Gastrointestinal

- minimally absorbed through gut

Elemental Mercury (Hg⁰)

Clinical Manifestations:

Lungs (acute inhalation)

- pneumonitis
- respiratory failure

Kidney is final target organ

- mercury accumulates as body tries to clear toxin

Significant prolonged or acute exposure

- salivation
- sweating
- mouth ulcers
- erethism
 - red palms/soles
 - emotional lability
 - memory impairment

Mercury (Hg)

Speciation:

- elemental (Hg^0)
- inorganic (mercurous, Hg^{1+} or mercuric, Hg^{2+})
- organic (methyl-, ethyl-, or phenylmercury)

Inorganic Mercury (Hg^{1+} and Hg^{2+})

Sources:

Inorganic mercury salts

mercurous (monovalent)
and mercuric (divalent)

disinfectant

antibacterial

antiparasitic

cathartic

diuretic

Mercurous chloride
(calomel)

teething powder, cholera

Exposure Pathways

Gastrointestinal

- local irritant
- can be very caustic
- little systemic absorption
unless the protective
barrier compromised

Skin

- poor systemic absorption
unless exposed to
large amounts

Inorganic Mercury (Hg^{1+} and Hg^{2+})

Clinical Manifestations:

Caustic nature can break down skin or mucosa, leading to

- kidney damage
- neurological damage

Prolonged exposure may cause

- peripheral neuropathy
- hypersensitivity reactions on skin or in kidney
- salivation
- sweating
- erethism

Mercury (Hg)

Speciation:

- elemental (Hg^0)
- inorganic (mercurous, Hg^{1+} or mercuric, Hg^{2+})
- organic (methyl-, ethyl-, or phenylmercury)

Organic Mercury (methyl, ethyl, phenyl)

Sources:

Methylmercury

- used as a crop fungicide
- ubiquitous in environment since microorganisms methylate elemental mercury

Ethylmercury

- thimerosal used as an antiseptic and vaccine preservative

Phenylmercury

- fungicide in latex paints

Organic Mercury (methyl, ethyl, phenyl)

Exposure Pathways

Gastrointestinal

- almost completely absorbed in gut because of lipid solubility

Nervous System

- easily crosses blood-brain barrier
- has affinity for certain nervous system cells (methyl)

Placenta

- easily crosses placenta, entering fetal circulation

Breast Milk

- easily accumulates and transferred in milk

Respiratory

- unstable phenyl-mercury bond can result in the inhalation of elemental mercury

Organic Mercury (methyl, ethyl, phenyl)

Clinical Manifestations:

Neurological signs and symptoms most prominent


- weakness
- paresthesia
- visual and auditory deficits
- tremor
- coma

Children and fetuses exceptionally vulnerable

- seizures
- psychomotor retardation
- visual and auditory impairment

Case Report on DiMeHg Exposure (*Clinical Description*)

- 48-year old chemistry admitted to Dartmouth Med. Ctr (1/20/97)
- Reported exposure to $(\text{Me})_2\text{Hg}$ on August 14, 1996
- Whole-blood Hg level was more than 1000 ug/L
- Chelation therapy (oral succimer, 10 mg/kg was begun on day 168
- Lab results: whole-blood Hg = 4000 ug/L (NR=1-8, toxic level >20); Urinary Hg=234 ug/L (NR 1-5, toxic level >50)
- Patient lapse into a coma (176 days after exposure): vegetative state
- Died on June 8, 1997 (298 days after exposure)



“Great Shock” The June 1997 death of Karen Wetterhahn from an accident that had occurred months earlier stunned the scientific community

Organic Mercury Poisoning

Environmental Contamination

Minamata Bay, Japan (1956)

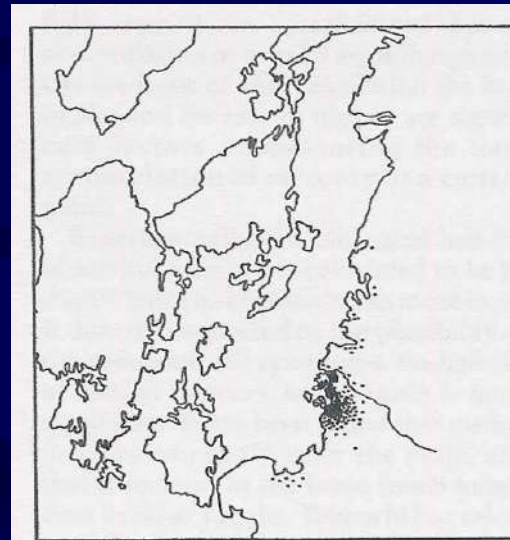
Iraq (1956, 1960, 1971)

Pakistan (1969)

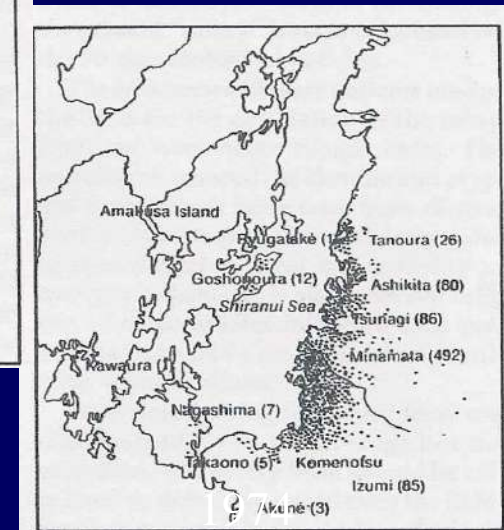
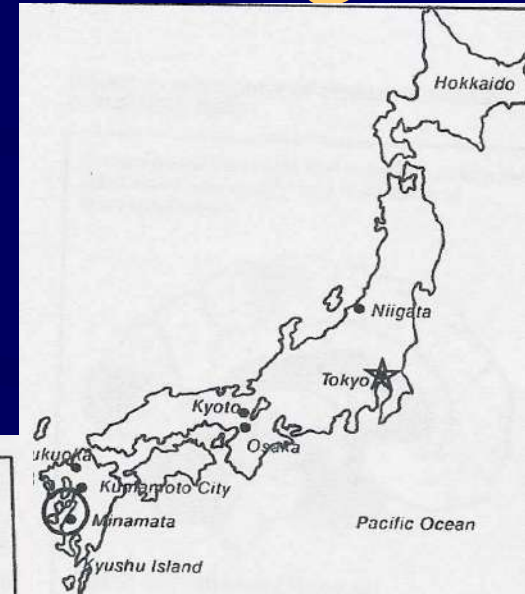Guatemala (1963)

Japan (1964)

Ghana (1967)



1962



Minamata, W. Eugene and Aileen Smith

Minamata Disease

Congenital:

Developmental delay

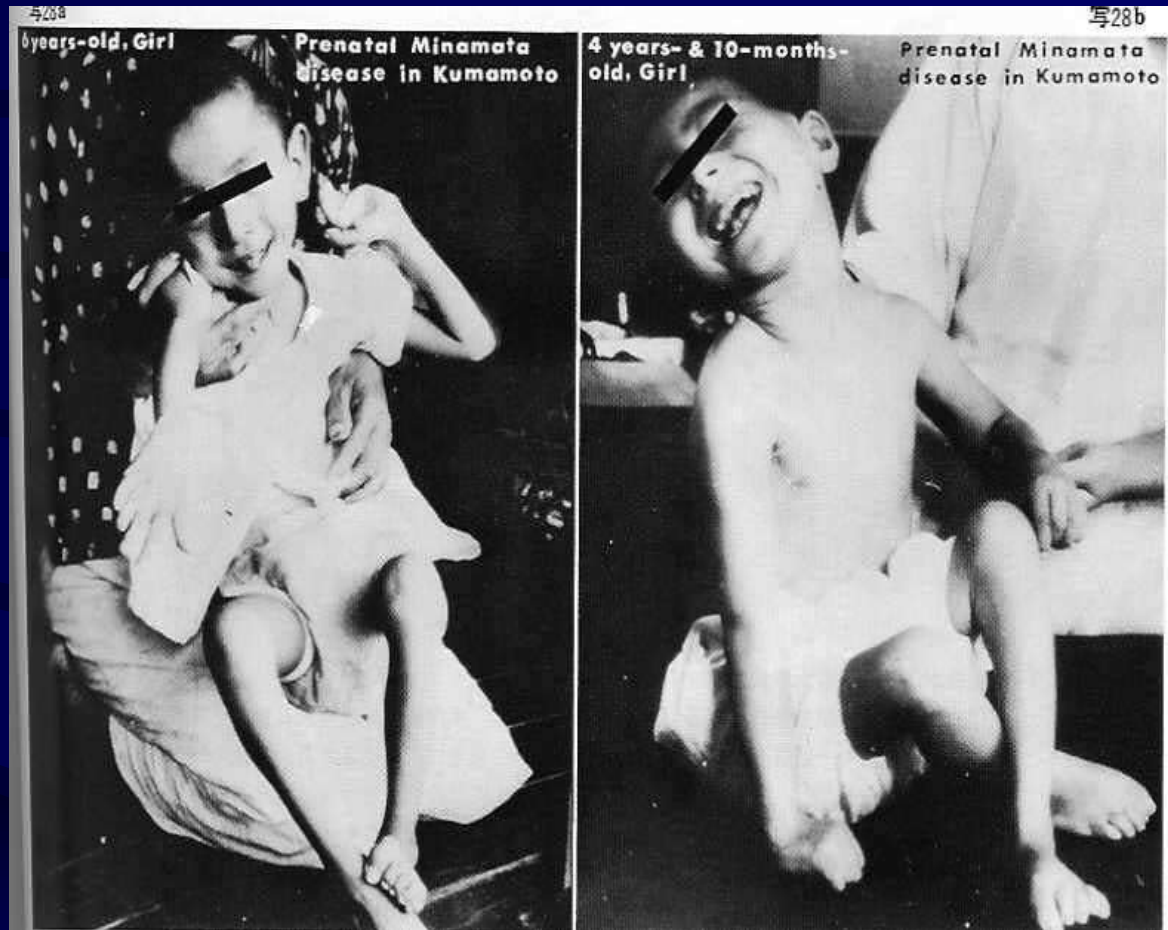- mental
- physical

Blindness

Deafness

Muscle atrophy

Seizures



Minamata, W. Eugene and Aileen Smith

Minamata Disease

Acquired

Numbness of extremities

Lack of coordination

hands

gait

speech

Weakness


Sensory loss

touch

vision

hearing

Seizures



Minamata, W. Eugene and Aileen Smith


Solutions

(Treatment Summary)

- Chelation therapy is the standard intervention for elemental and inorganic poisoning (eg. BAL, DMPS, EDTA)
- However, chelating agents may increase the CNS organic mercury concentration.
- Chelating agents increase the mercury excretion (e.g., BAL is not recommended for chronic exposure because it enhances brain uptake of Hg)
- However, there is little evidence to show that chelation arrests or decreases the toxic effects of chronic mercury poisoning.
- Indications for chelation are not well established.
However, chelation is often used empirically in severe acute cases.

Man and Mercury: Learning for the Future

Neither treatment nor
tragedy need occur if
prevention prevails...



Minamata, W. Eugene and Aileen Smith



Thank you!