



Hepatotoxicity of Metals

Florabel G. Mullick, M.D., Dr. Sc., SES



Acute Hepatotoxicity

- Acute Hepatocellular
Panlobular degeneration
Mononucleosis-like
Submassive necrosis
Massive necrosis
Combined hepatocellular and cholestatic

Acute Hepatotoxicity

- Acute Cholestatic; Pure;
+hepatocellular injury;
+bile duct injury, = cholangitis
- Microvesicular steatosis
- Vasculitis, hypersensitivity-type
- Angiitis, necrotizing

Chronic Reactions

- Chronic hepatitis
- Chronic intrahepatic cholestasis
- Macrovesicular steatosis
- Phospholipidosis

Chronic Reactions

- Granulomatous reactions
- Fibrosis
- Cirrhosis
- Sinusoidal dilation

Chronic Reactions

- *Peliosis hepatis*
- *Veno-occlusive disease*
- *Hepatic vein thrombosis*
- *Neoplasia, benign & malignant*

Hepatotoxicity of Metals

Modes of Exposure

- Ingestion: Accidental, suicidal, industrial, domestic, medicinal (prescription of folk remedies)
- Inhalation
- Absorption from skin

Hepatotoxicity of Metals

The Culprits (1)

- Aluminum
- Barium
- Cadmium
- Copper
- Iron
- Arsenic
- Beryllium
- Chromium
- Gold
- Lead

Hepatotoxicity of Metals

The Culprits (2)

- Manganese
- Phosphorus
- Thallium
- Titanium
- Nickel
- Silver
- Thorium
- Zinc

Hepatotoxicity of Metals

Identification/Quantitation of Metals

(1)

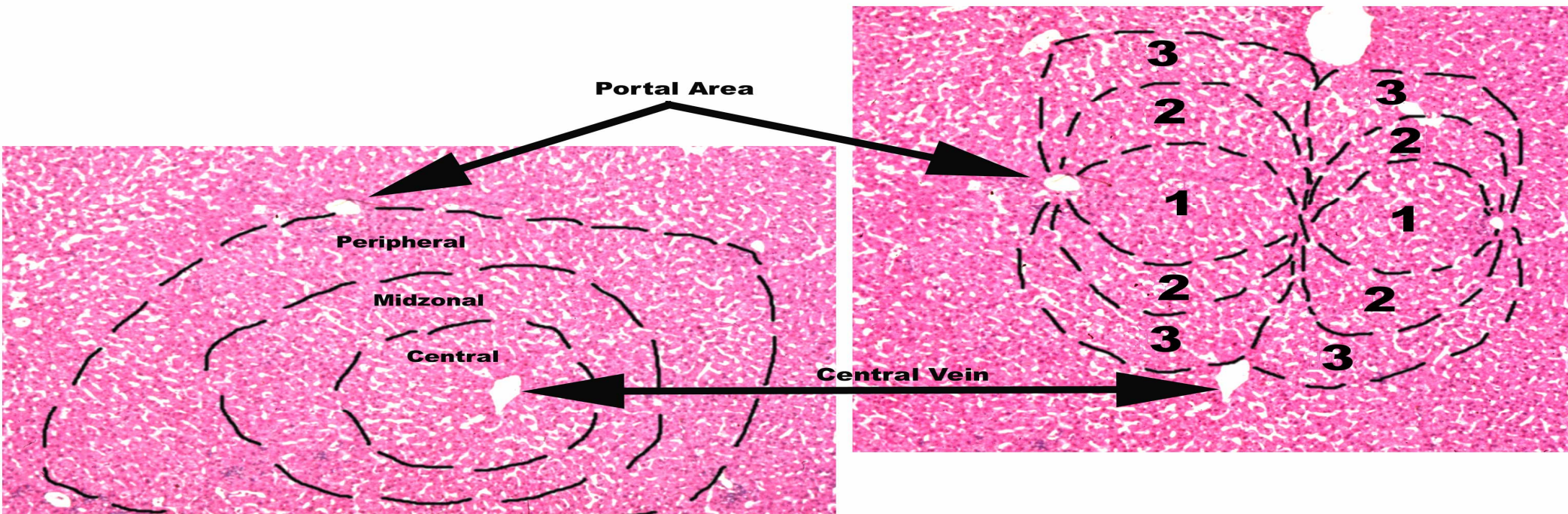
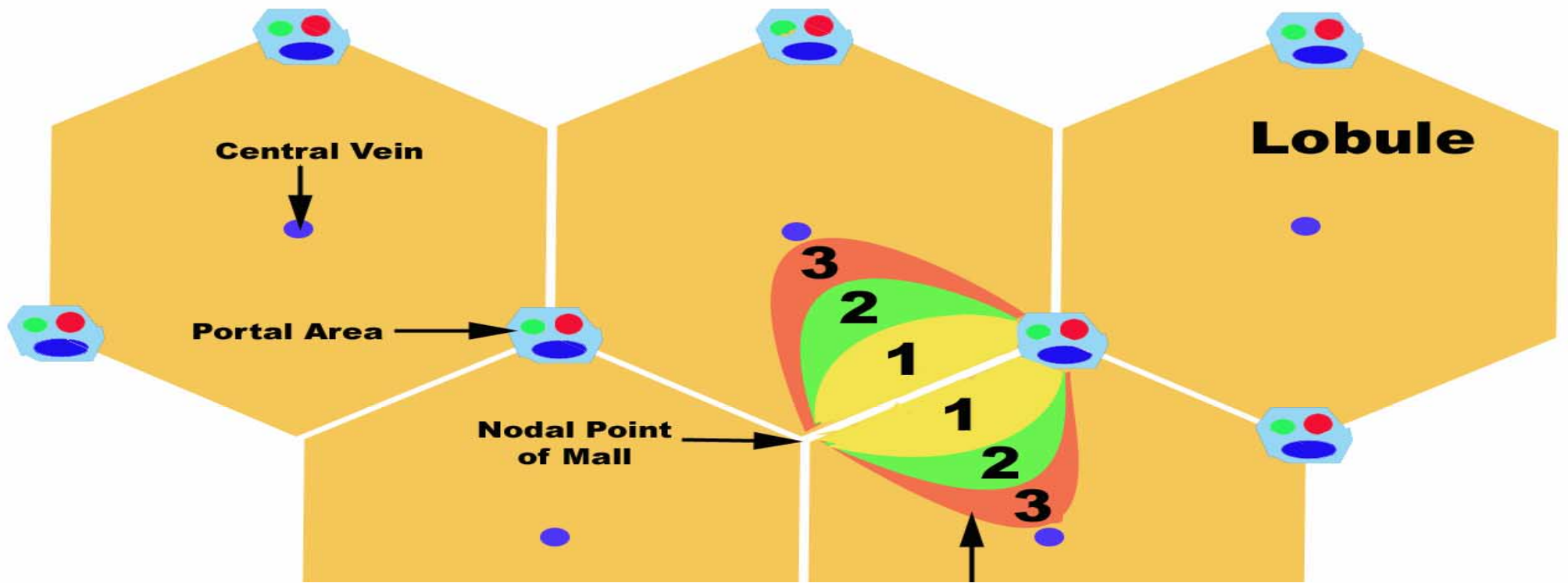
- Histopathology: Brown (e.g. Fe) or black pigment (e.g. Au or Ti)
- Polarizing microscopy (e.g. Au, Ti, Ba)
- Special stains: Prussian blue (Fe); rhodanine (Cu); Victoria blue (Cu-binding protein)

Hepatotoxicity of Metals

Identification/Quantitation of Metals

(2)

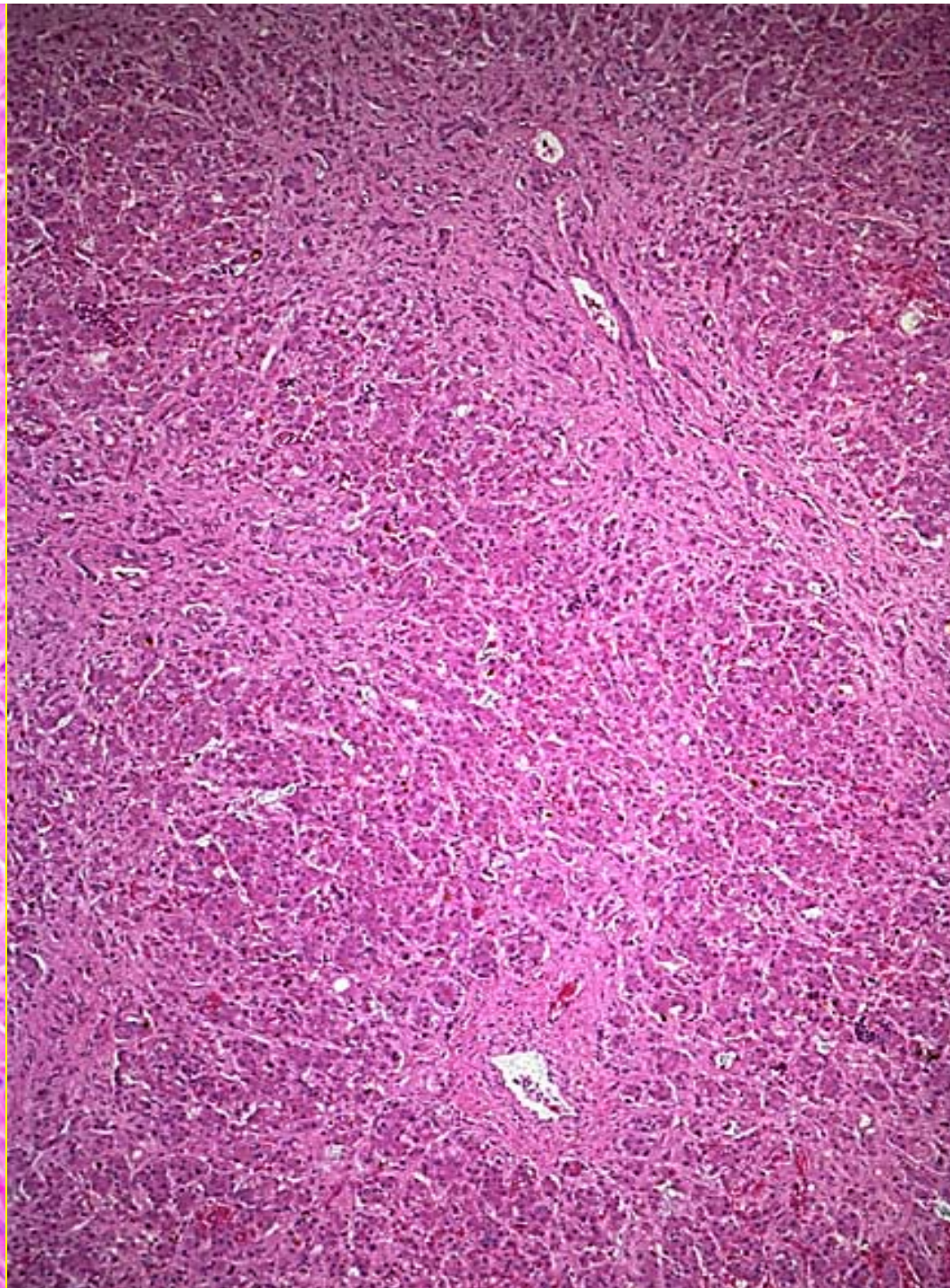
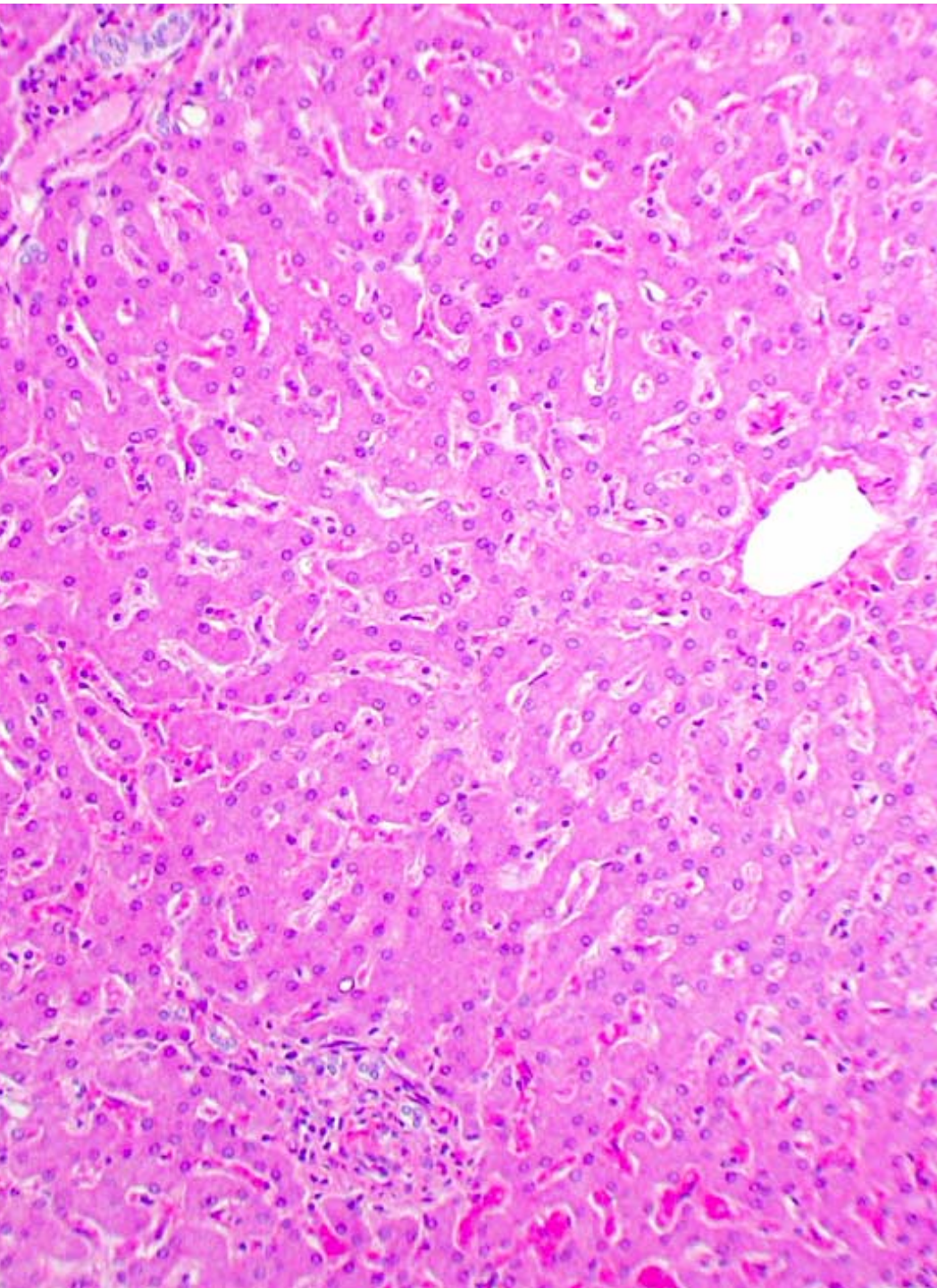
- Scanning EM and X-ray microanalysis
- Confocal Raman microscopy
- Atomic absorption spectrophotometry
 - Flame AAS
 - Graphite-furnace AAS
 - Inductively Coupled Plasma (ICP) and ICP-Mass spectrometry

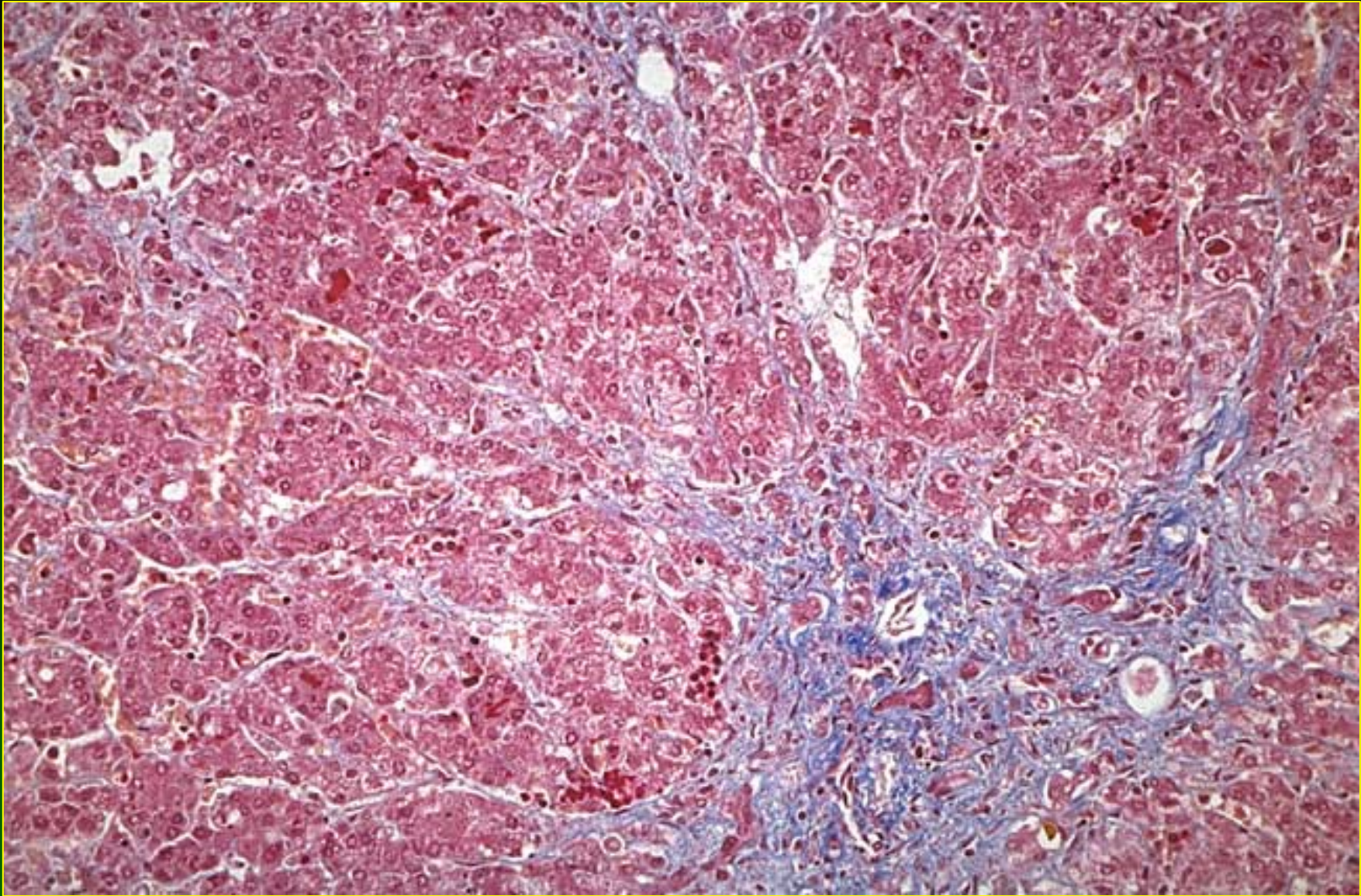


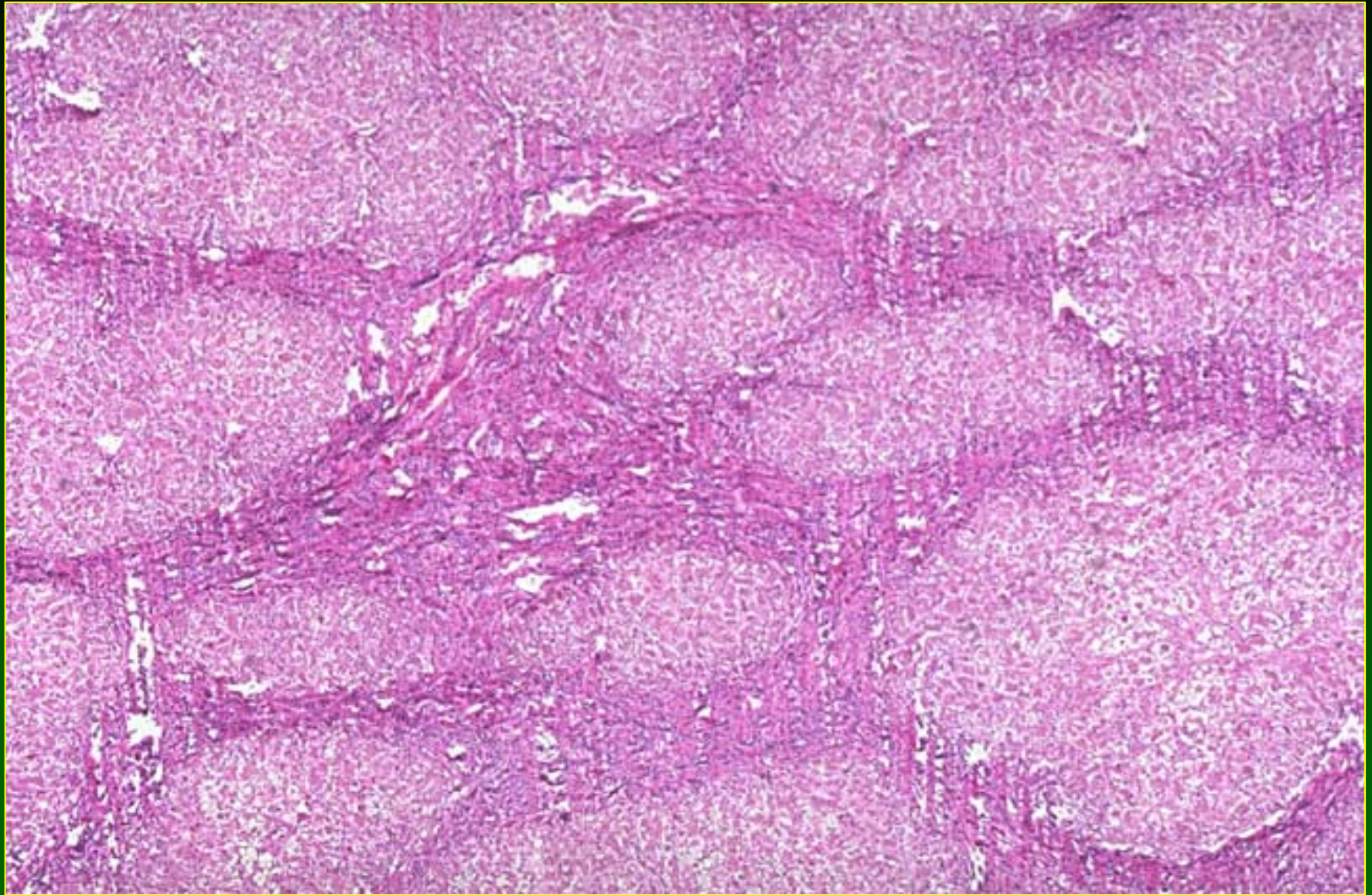
Hepatotoxicity of Metals

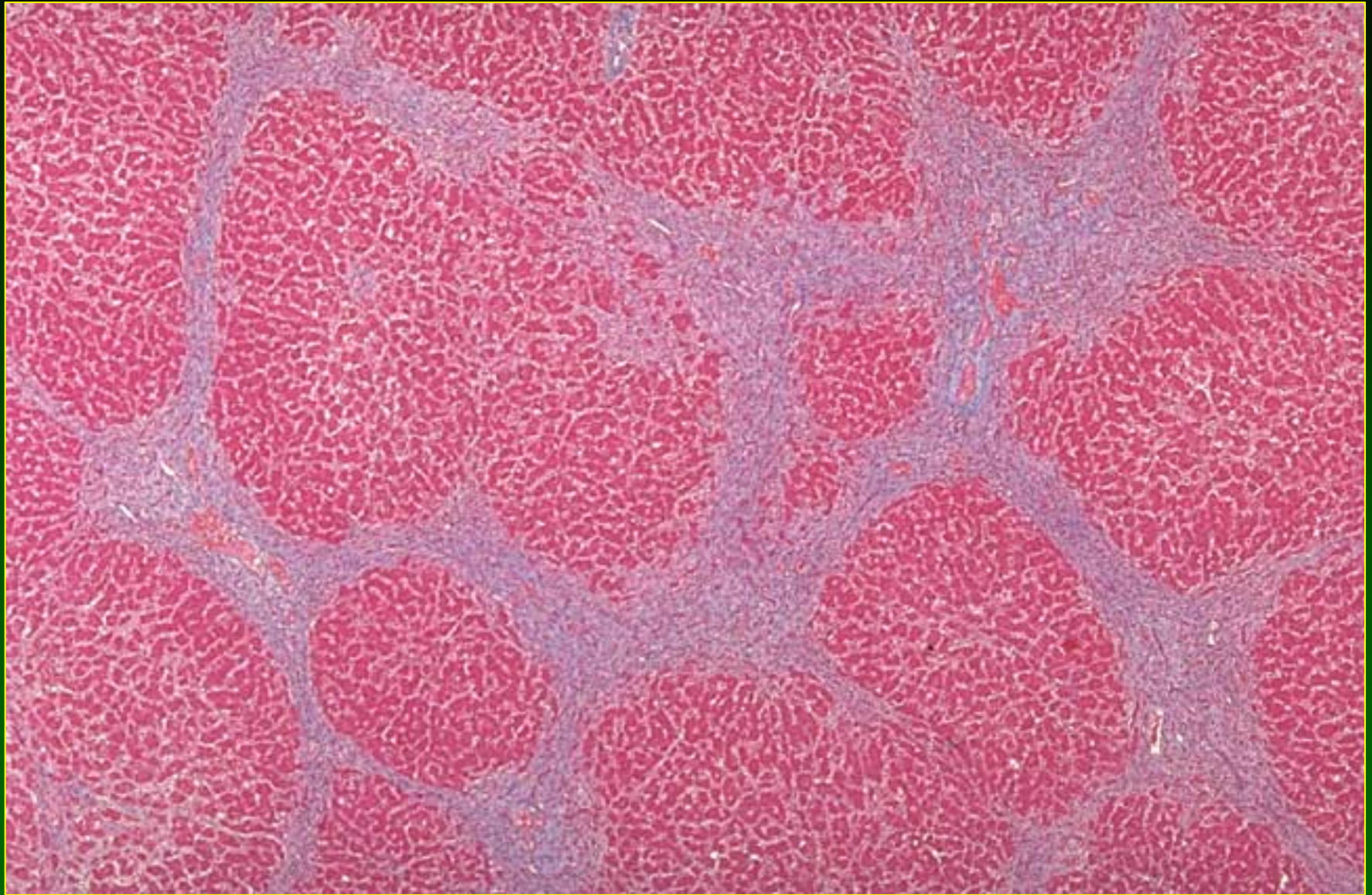
Aluminum

- Non-caseating granulomas in patients on long term hemodialysis (Kurumay et al, 1989)
- Contributes to hepatic injury in children on total parenteral nutrition (Klein et al, 1984)





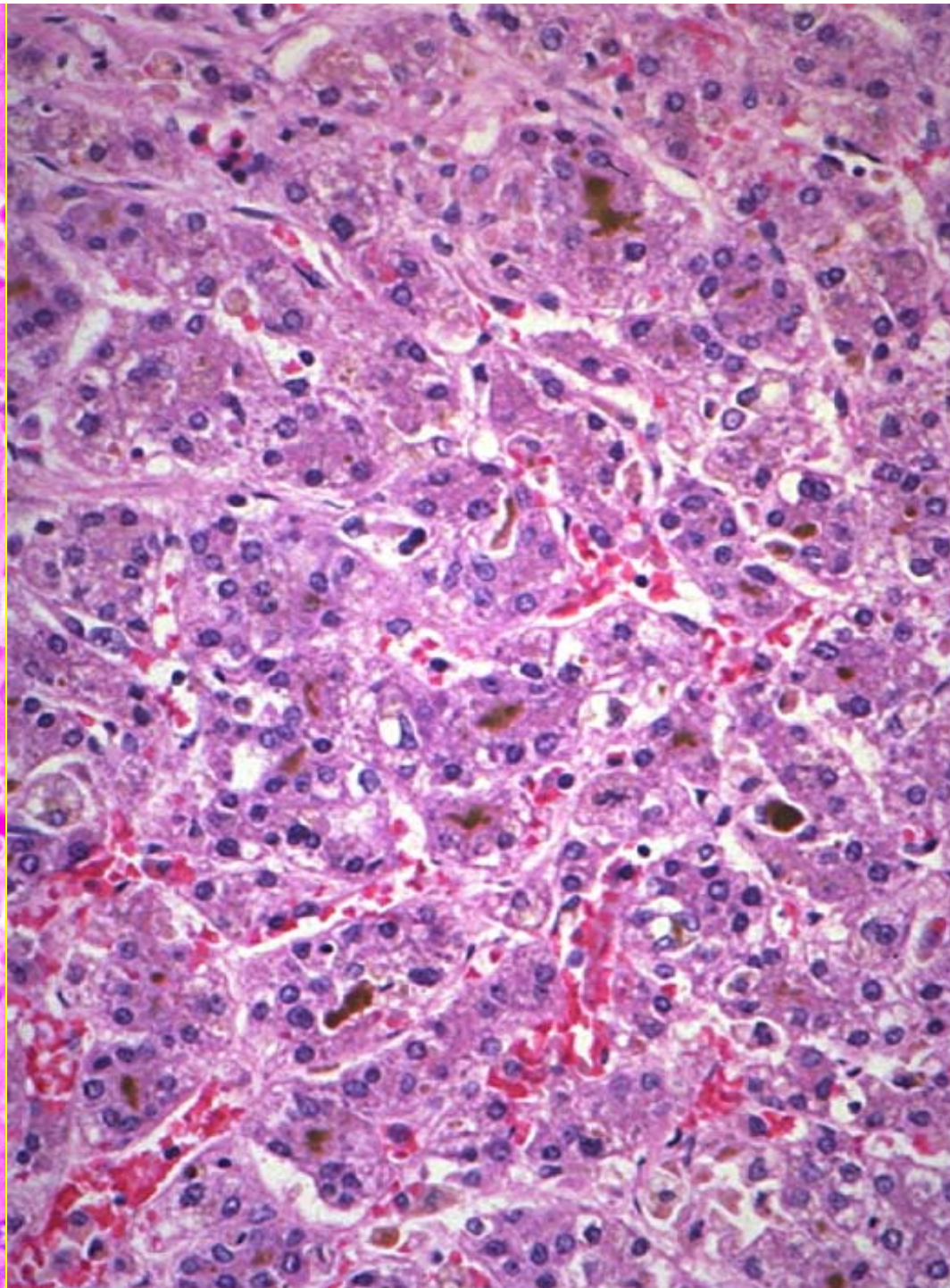
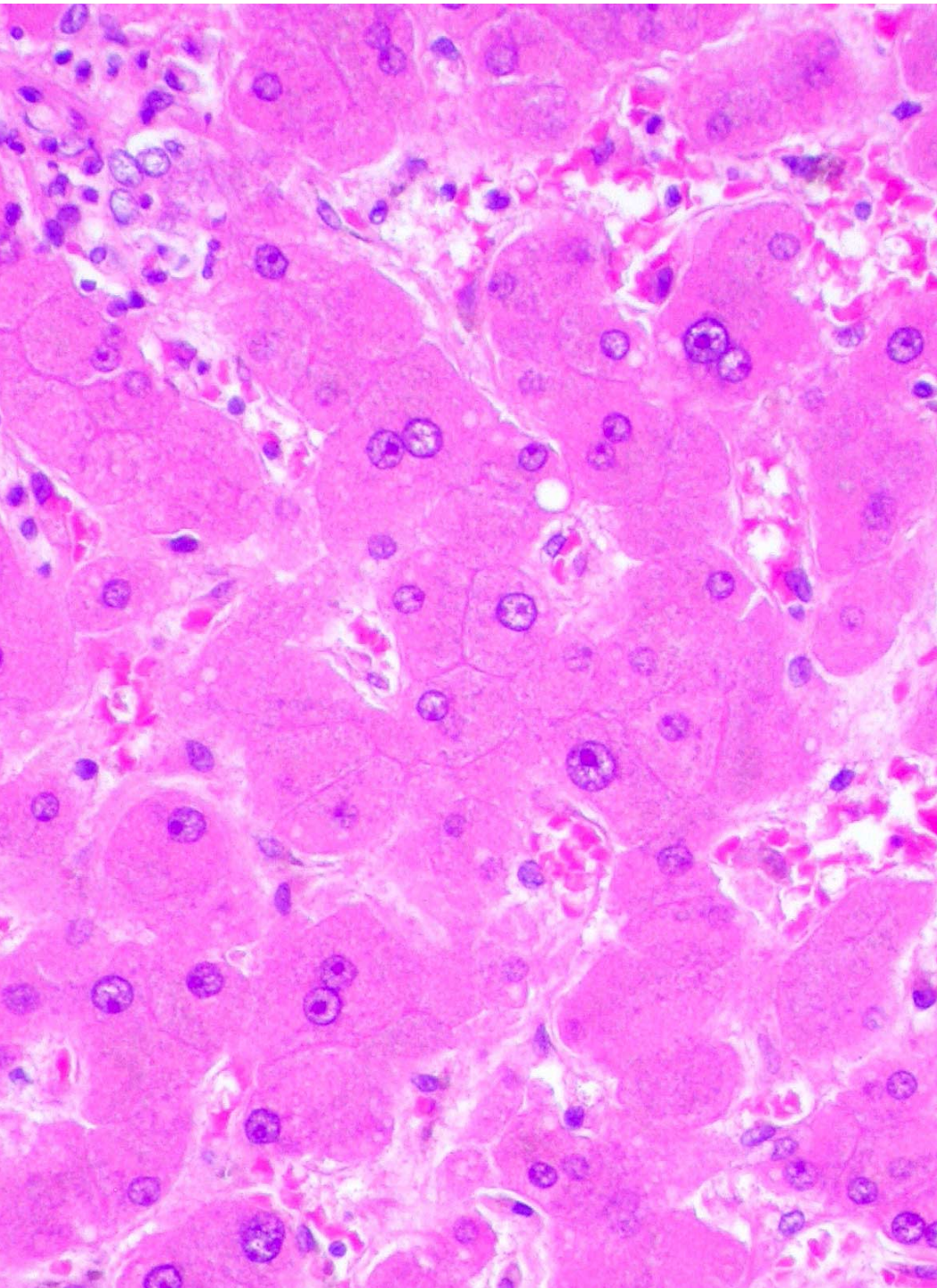




Hepatotoxicity of Metals

Arsenic (1)

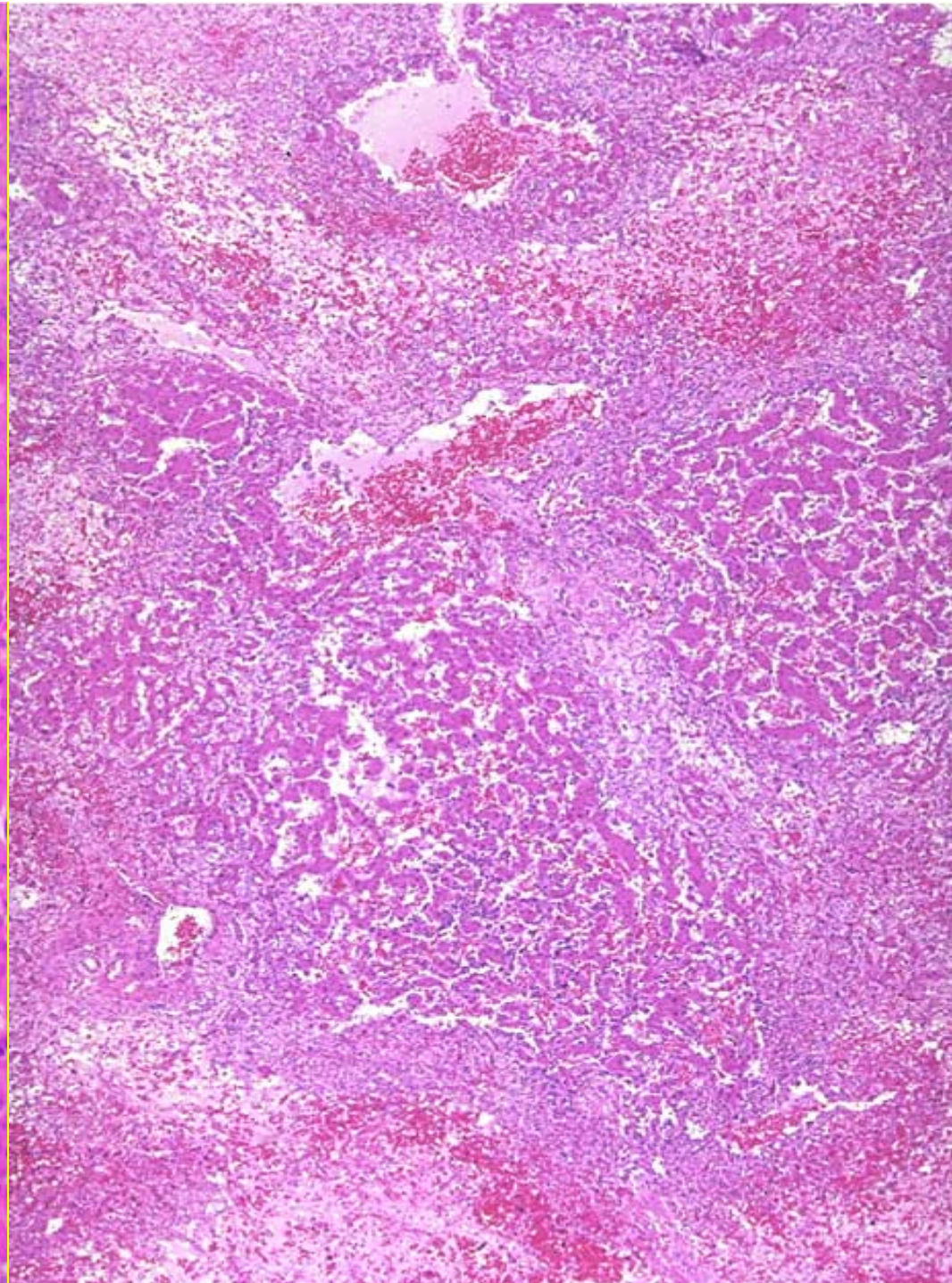
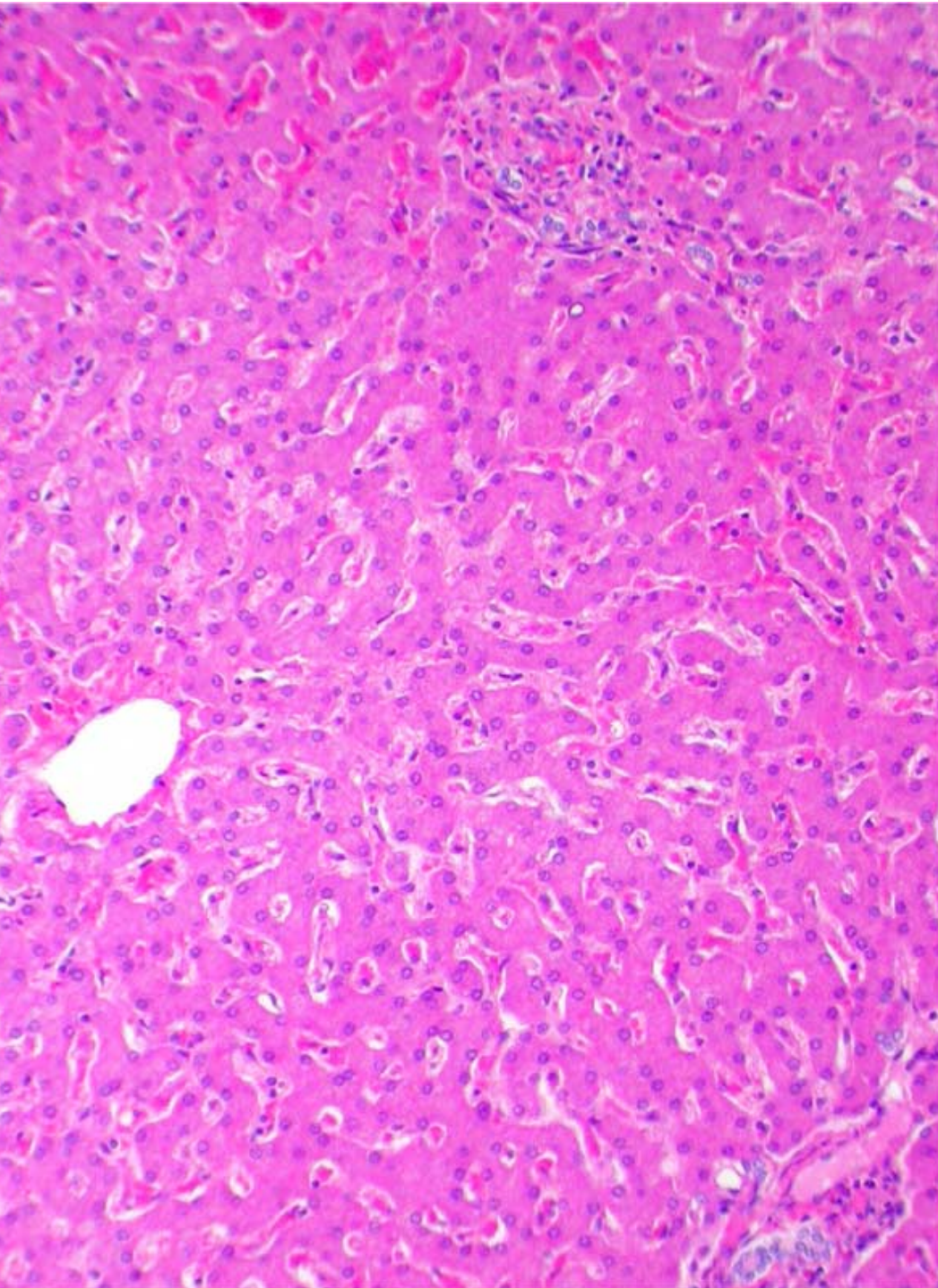
- Acute Toxicity
 - Intrahepatic cholestasis
 - Steatosis
 - Zone 3 necrosis
 - ↑ Mitotic activity
 - Venocclusive disease

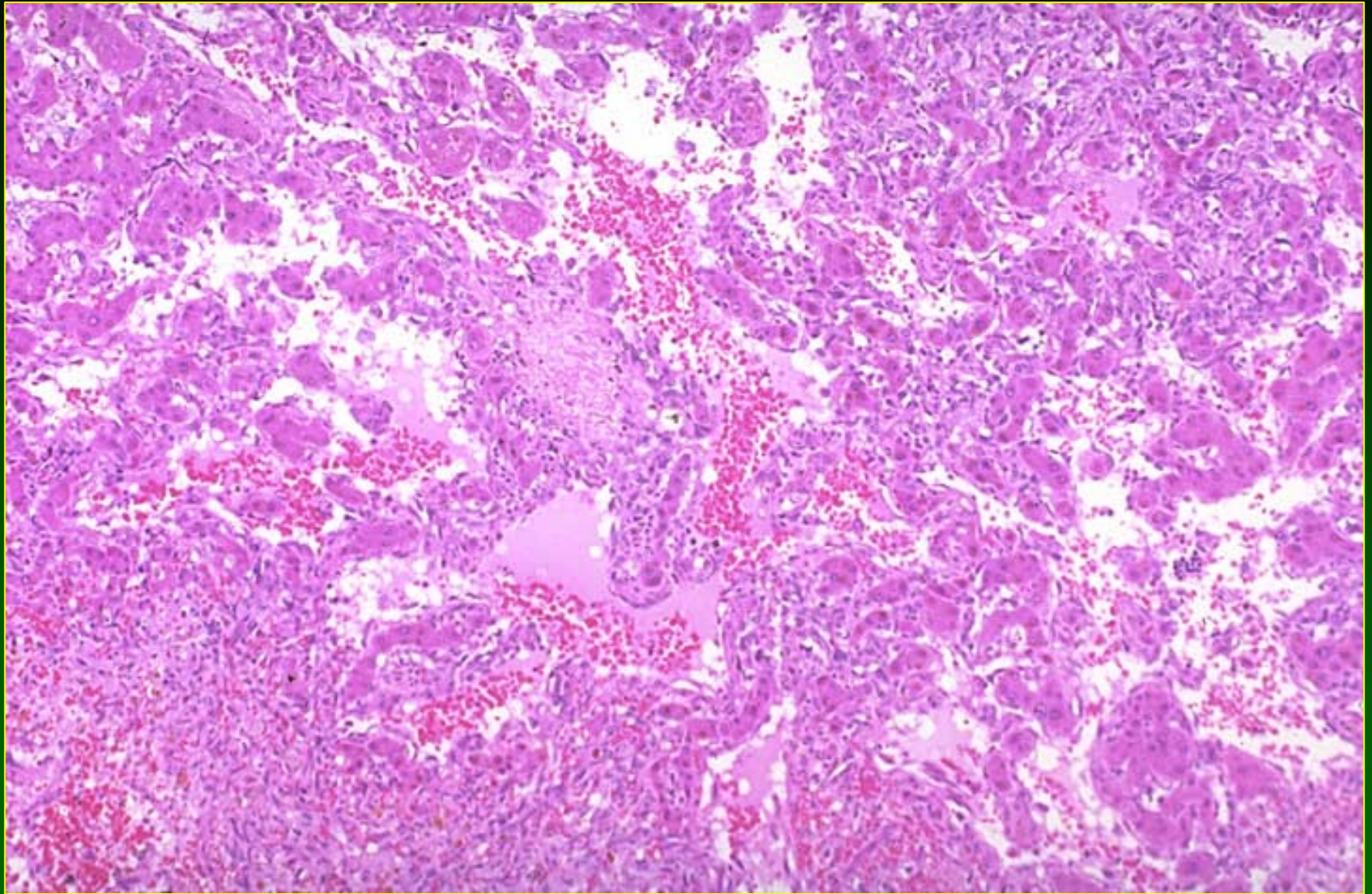


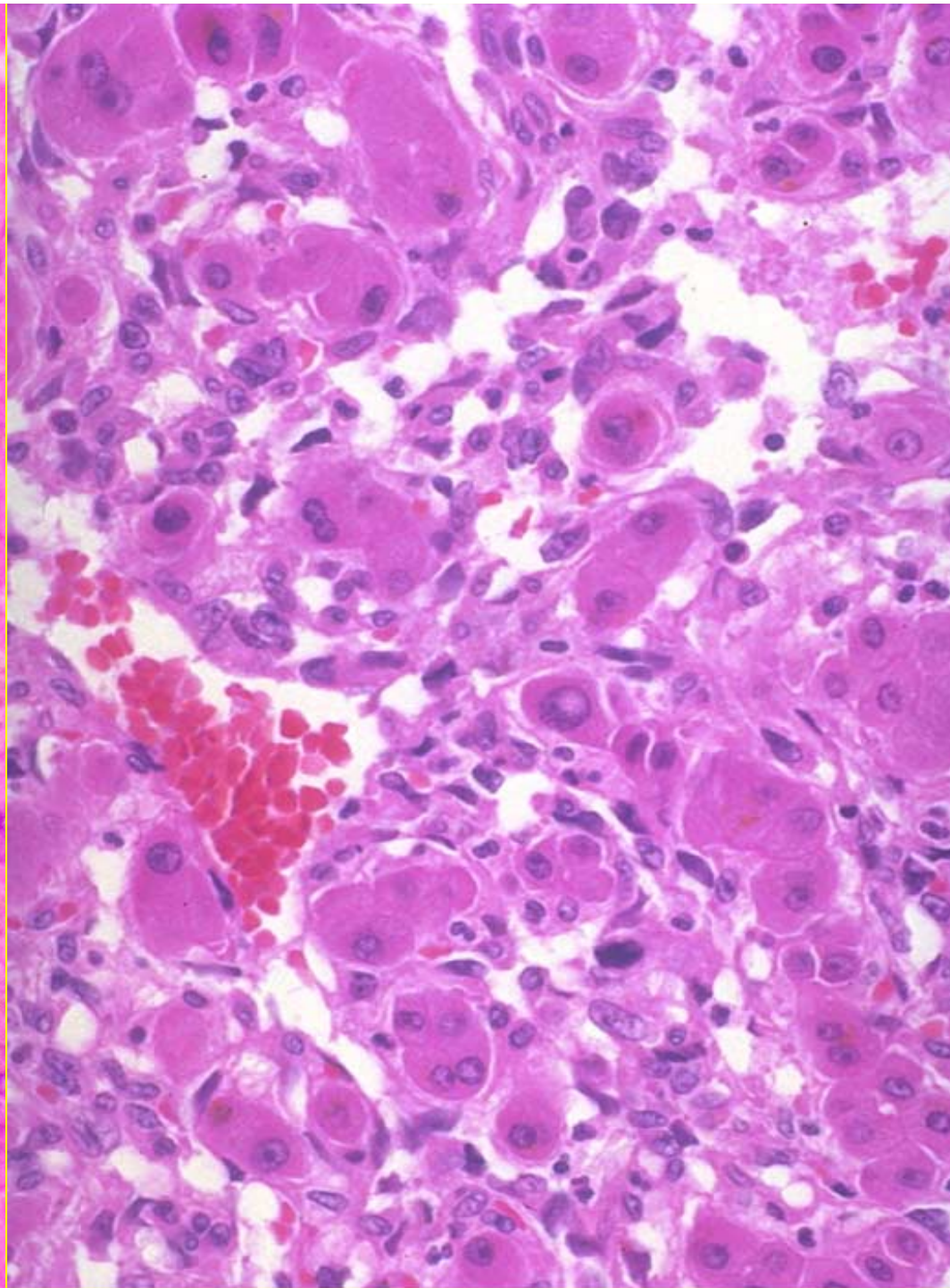
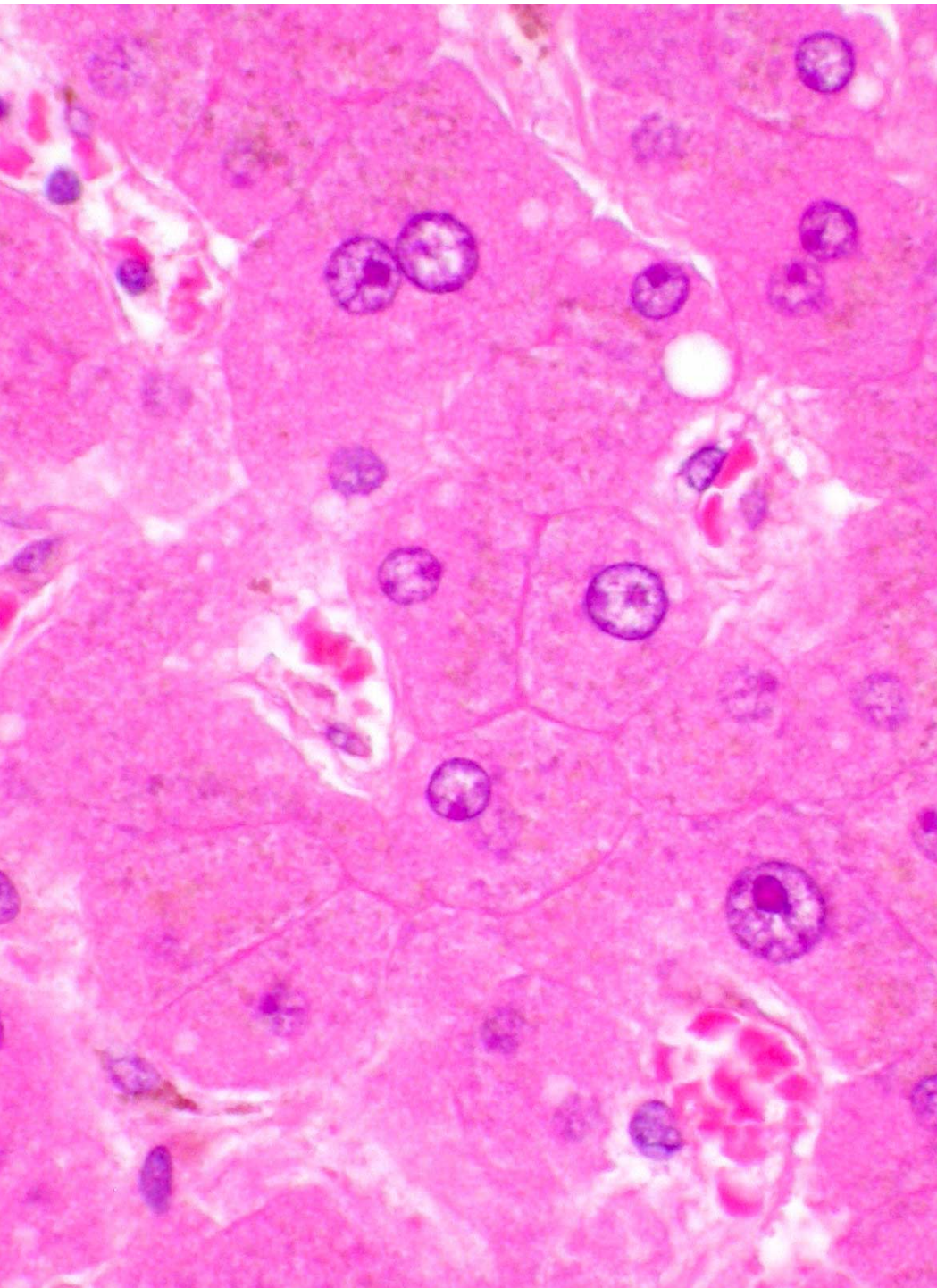
Hepatotoxicity of Metals

Arsenic (2)

- Chronic Toxicity
 - Hepatoportal sclerosis
 - Systemic arterial disease
 - Cirrhosis
 - Angiosarcoma
 - Hepatocellular carcinoma



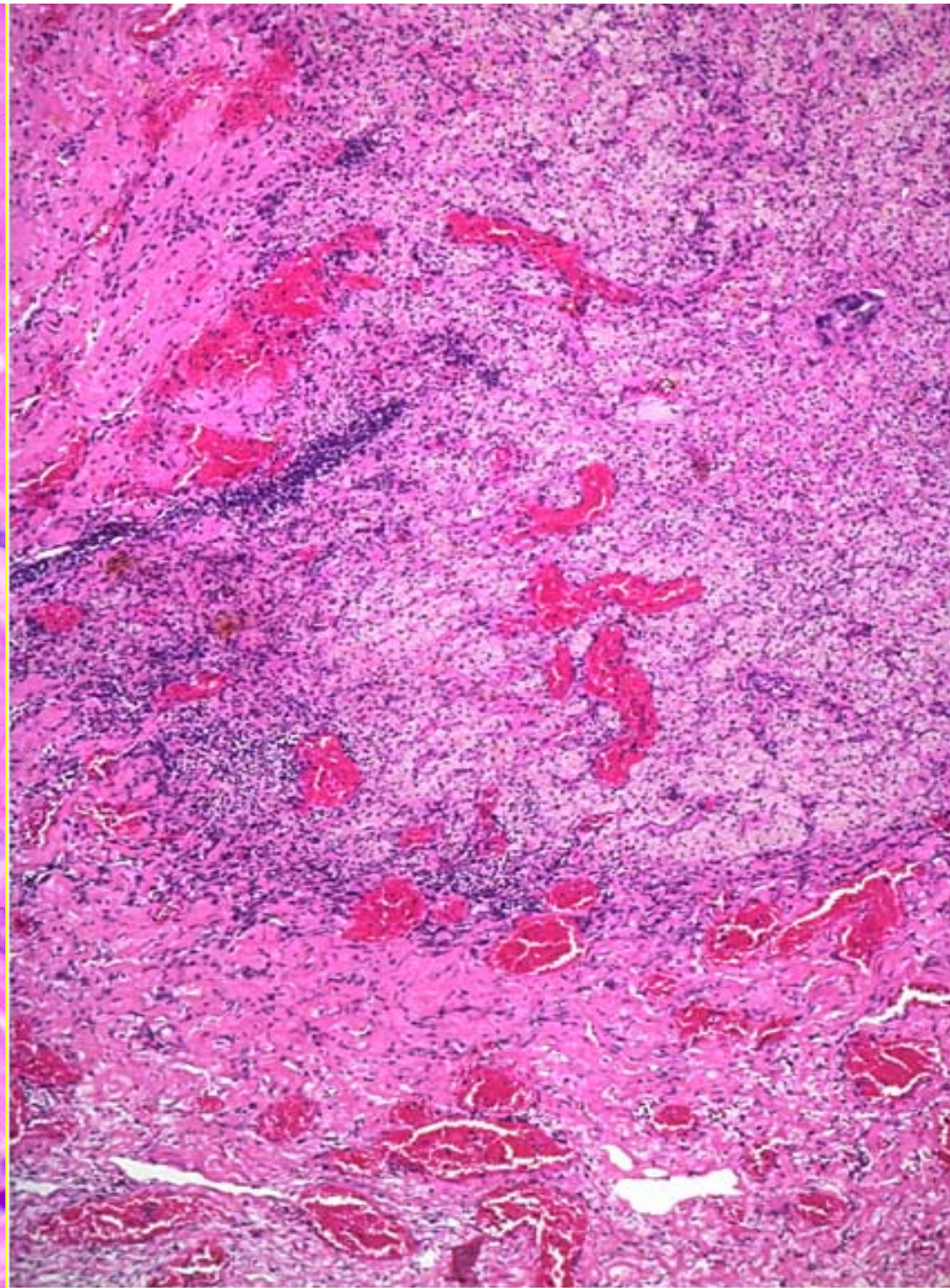
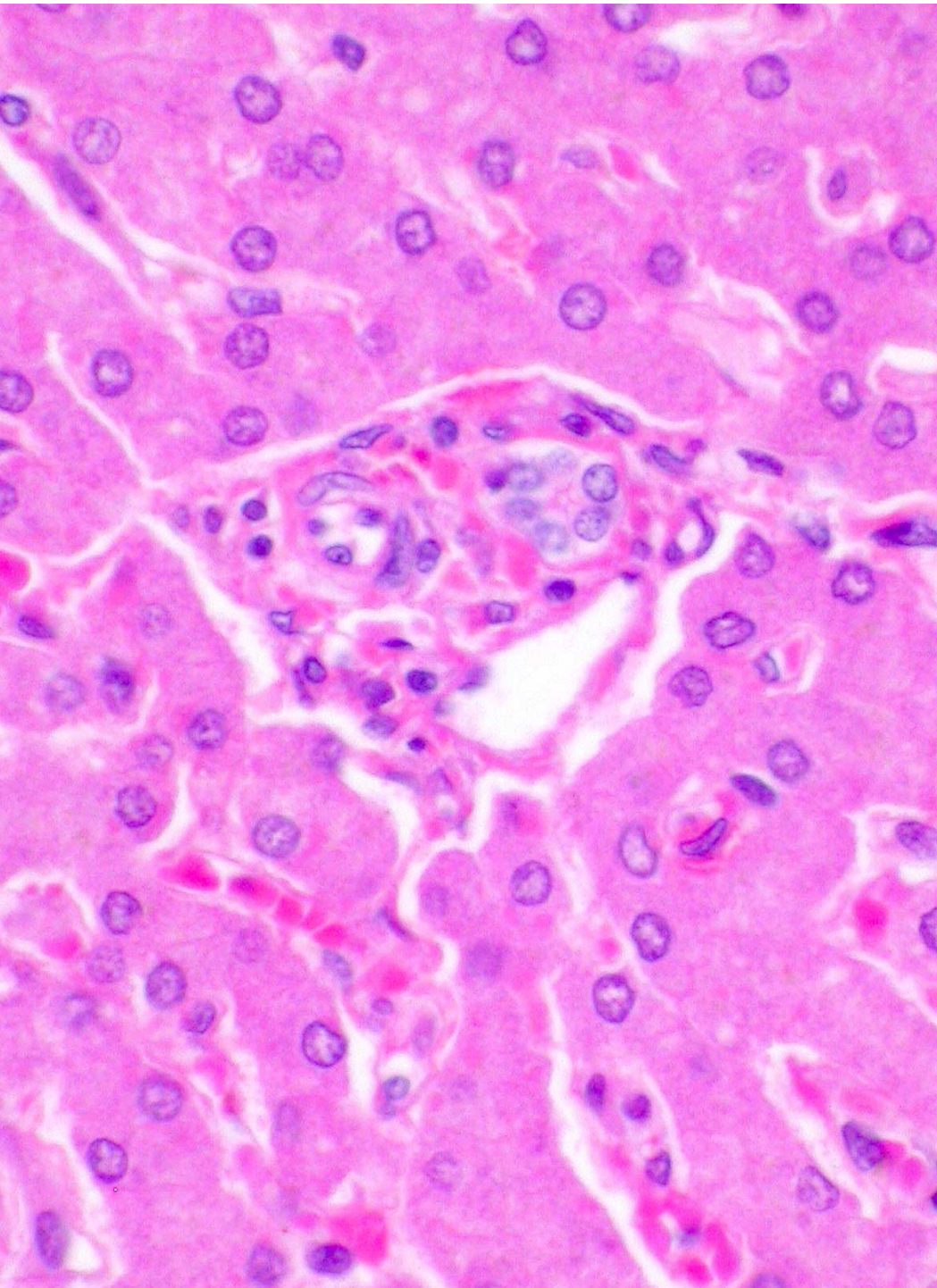


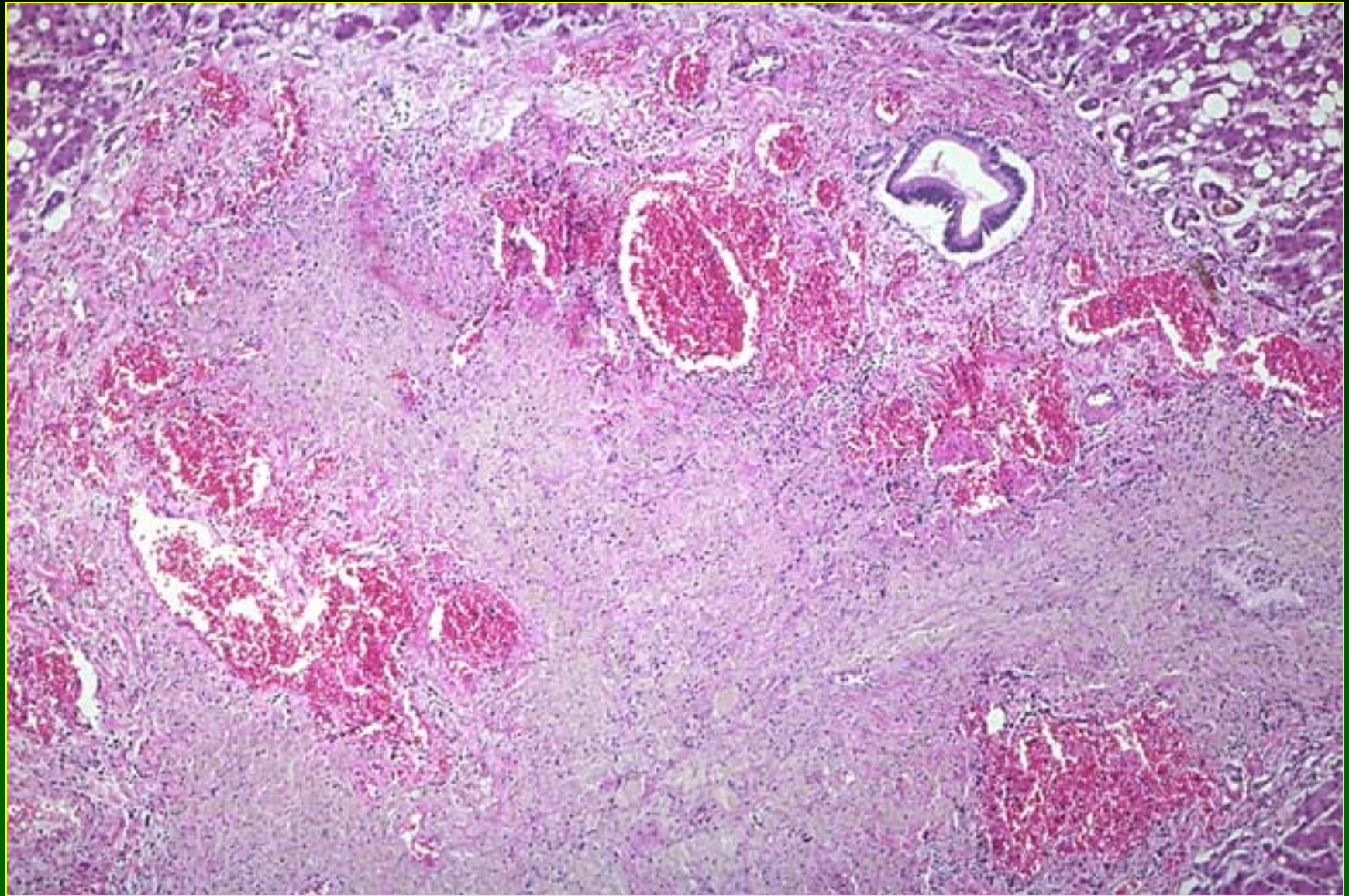


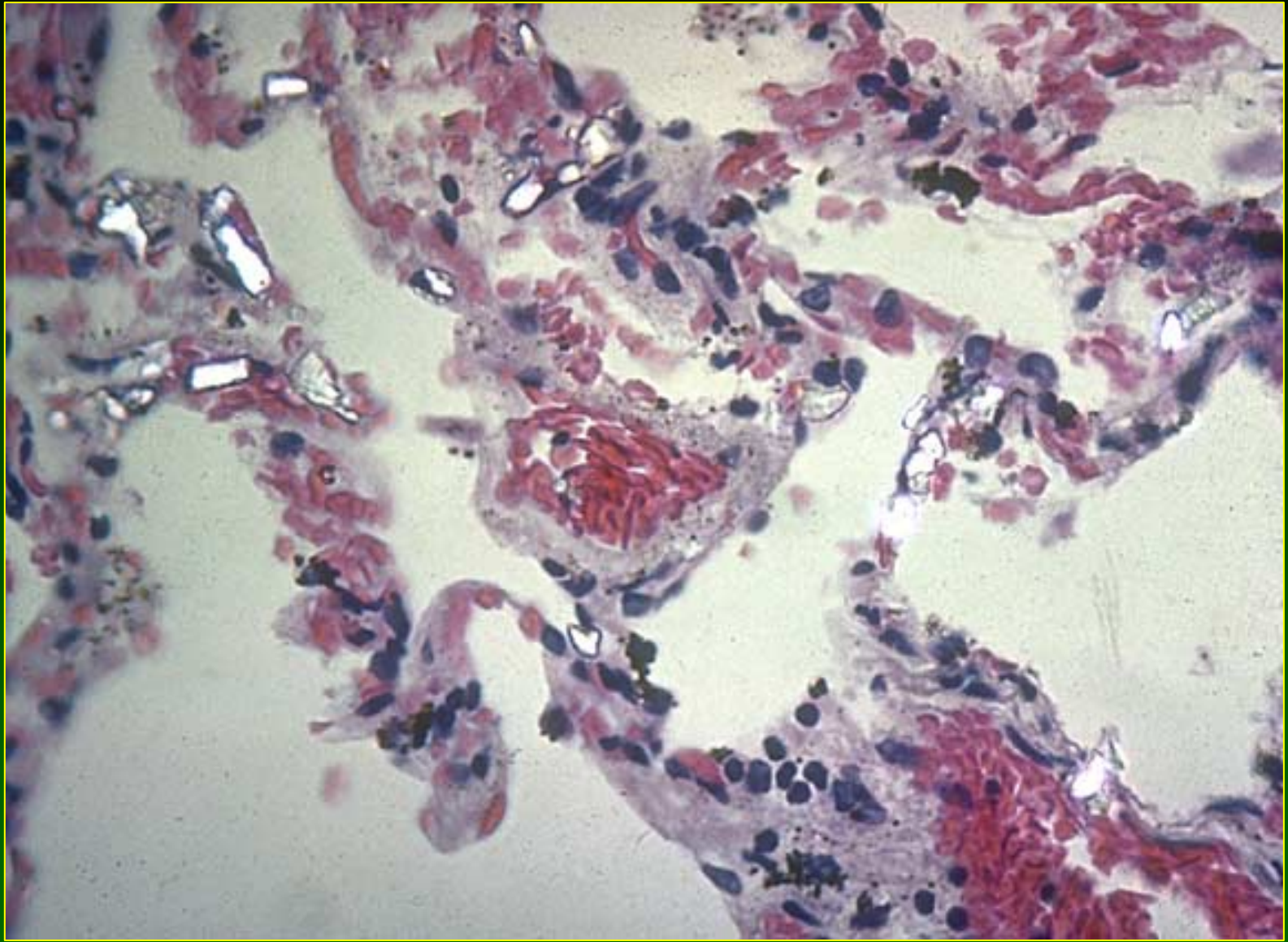
Hepatotoxicity of Metals

Barium

- Intravasation of BaSO_4 enema into portal venous system → portal pylephlebitis or liver abscess





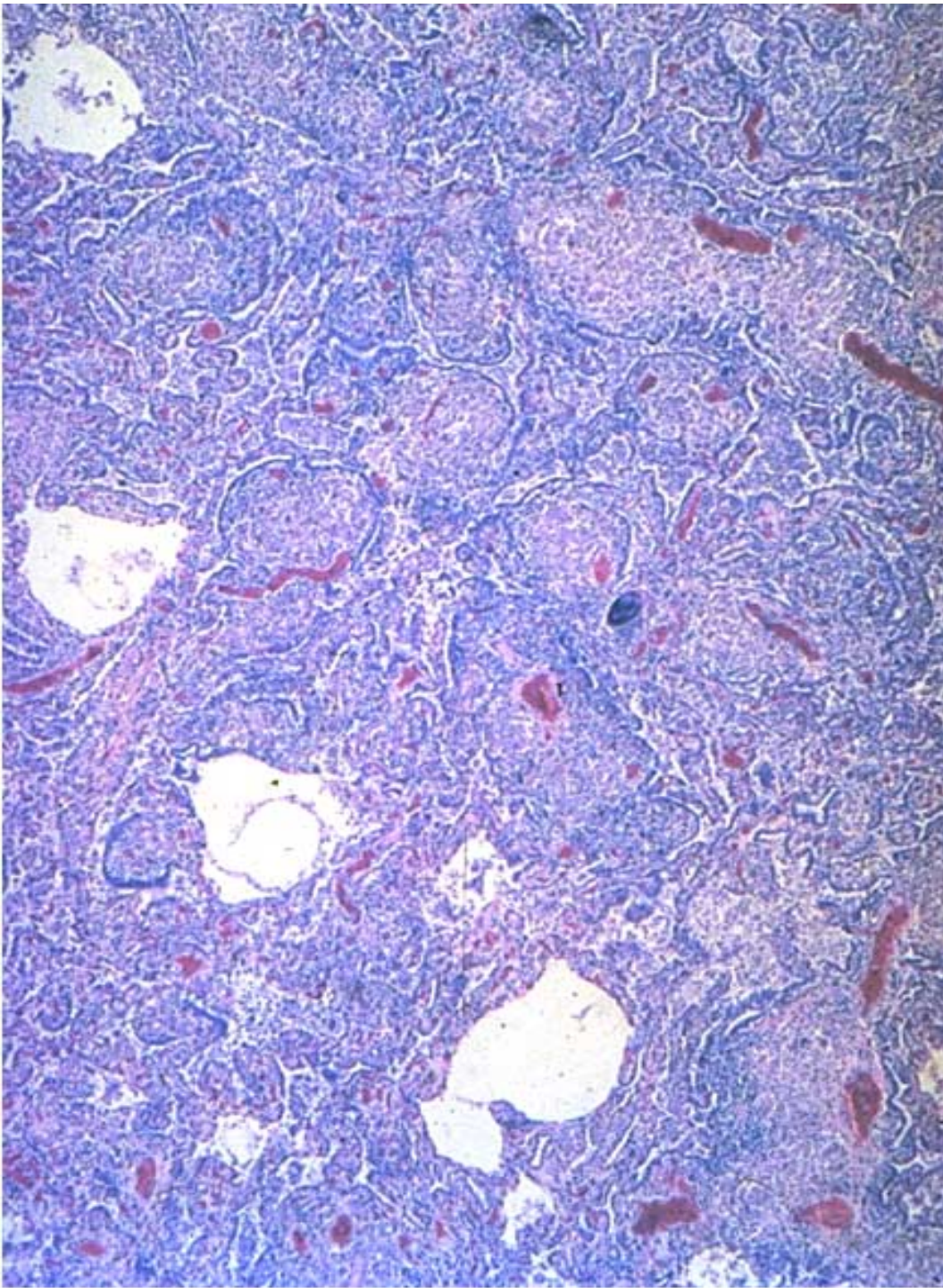
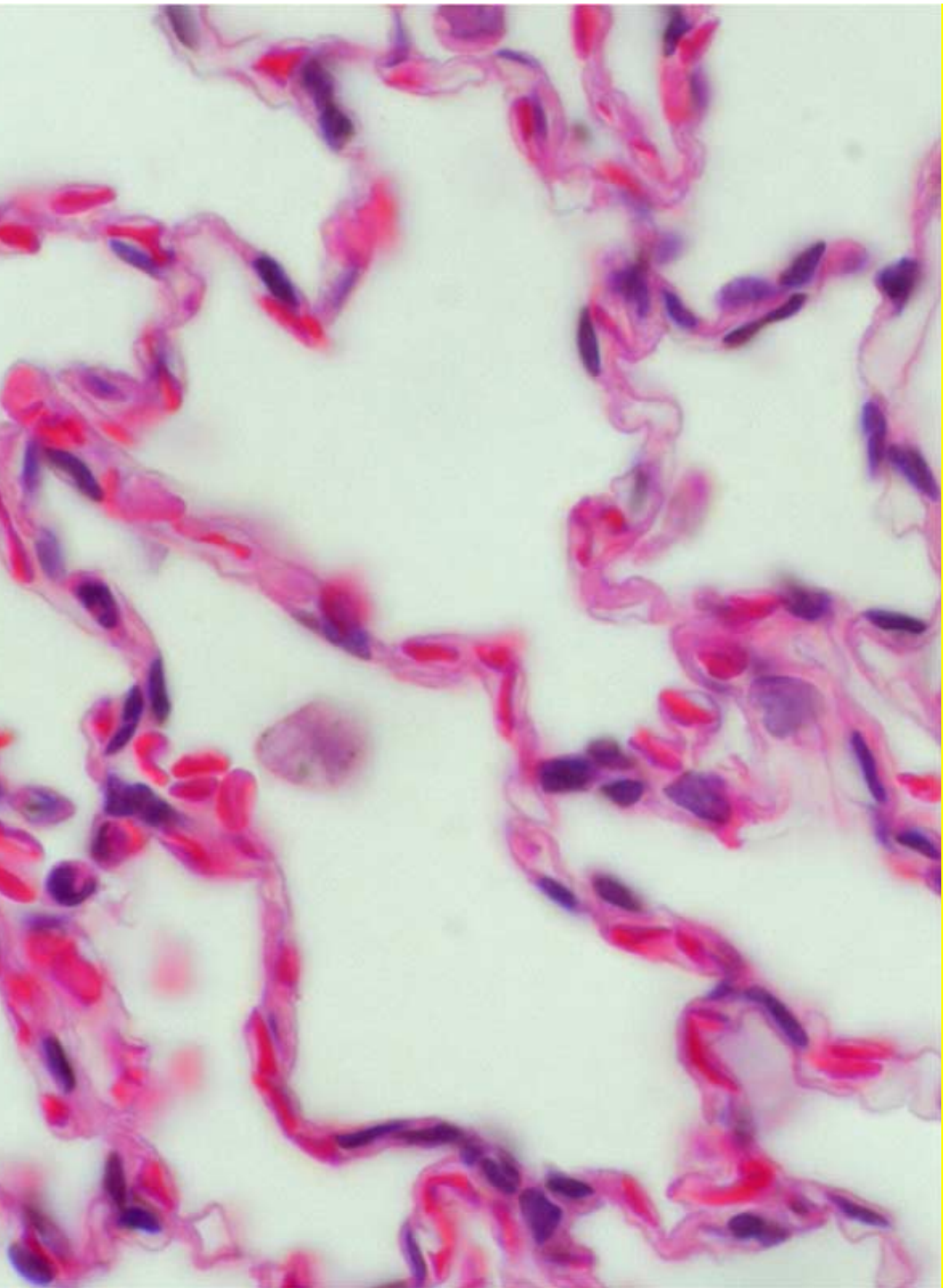


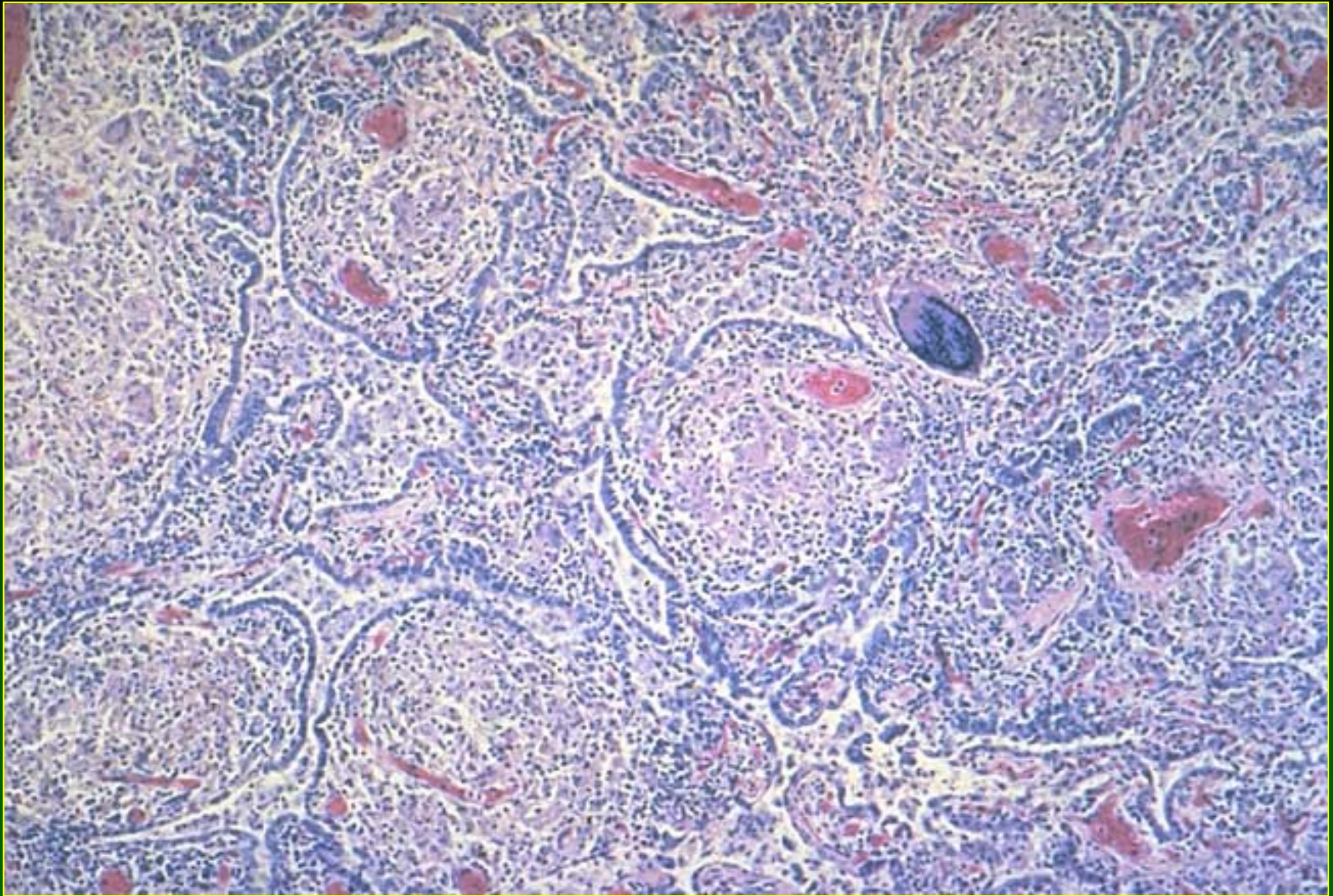
Hepatotoxicity of Metals

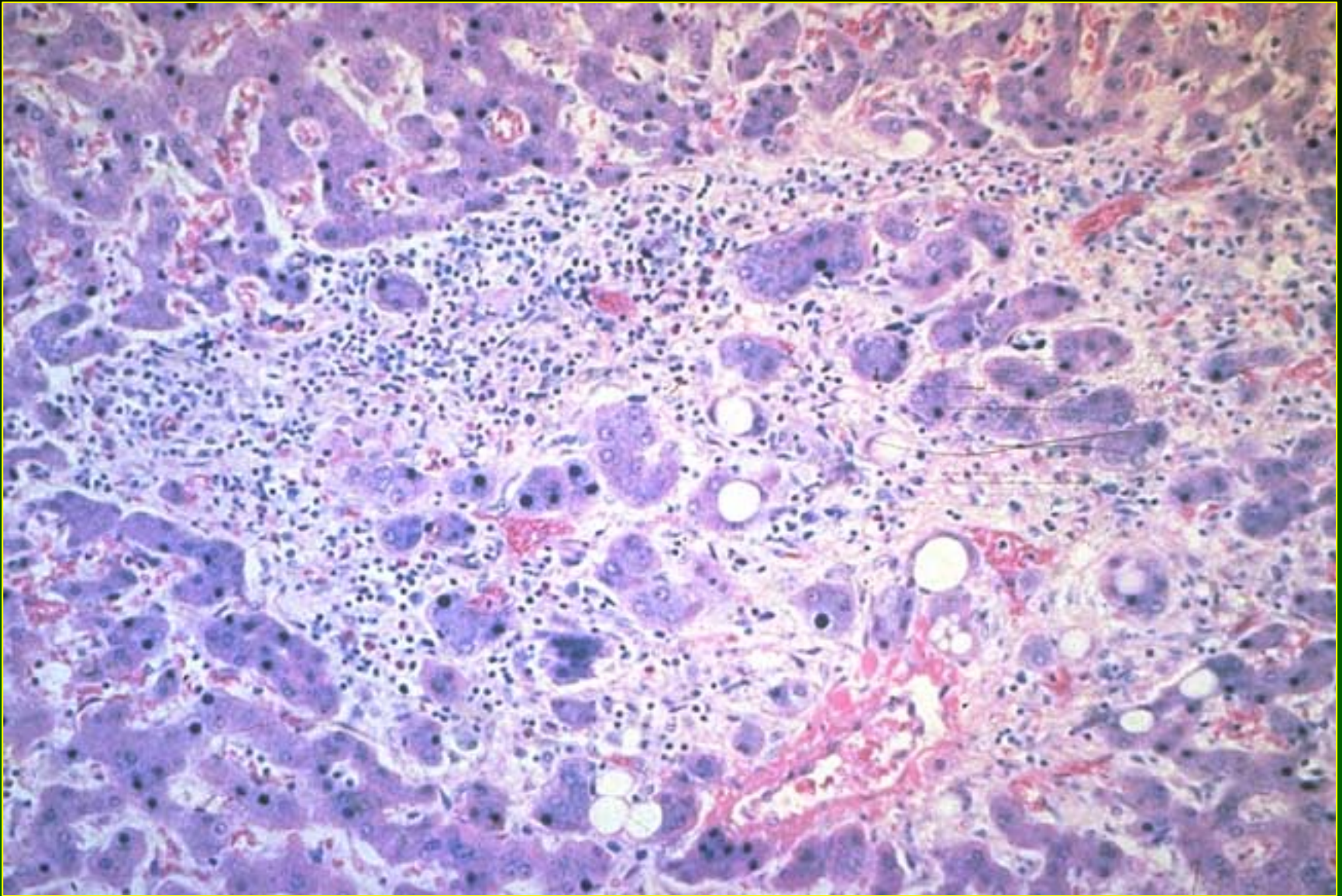
Beryllium

- Noncaseating, epithelioid granulomas in chronic beryllium disease (berylliosis)
- Midzonal hepatic necrosis (exp.)

- Male, age 28 years
- Occupation chemist
- Exposure: Beryllium and other materials during schooling and employment. 15 pound loss and shortness of breath. Died one year later. Lung and liver showed granulomas and focal necrosis respectively.





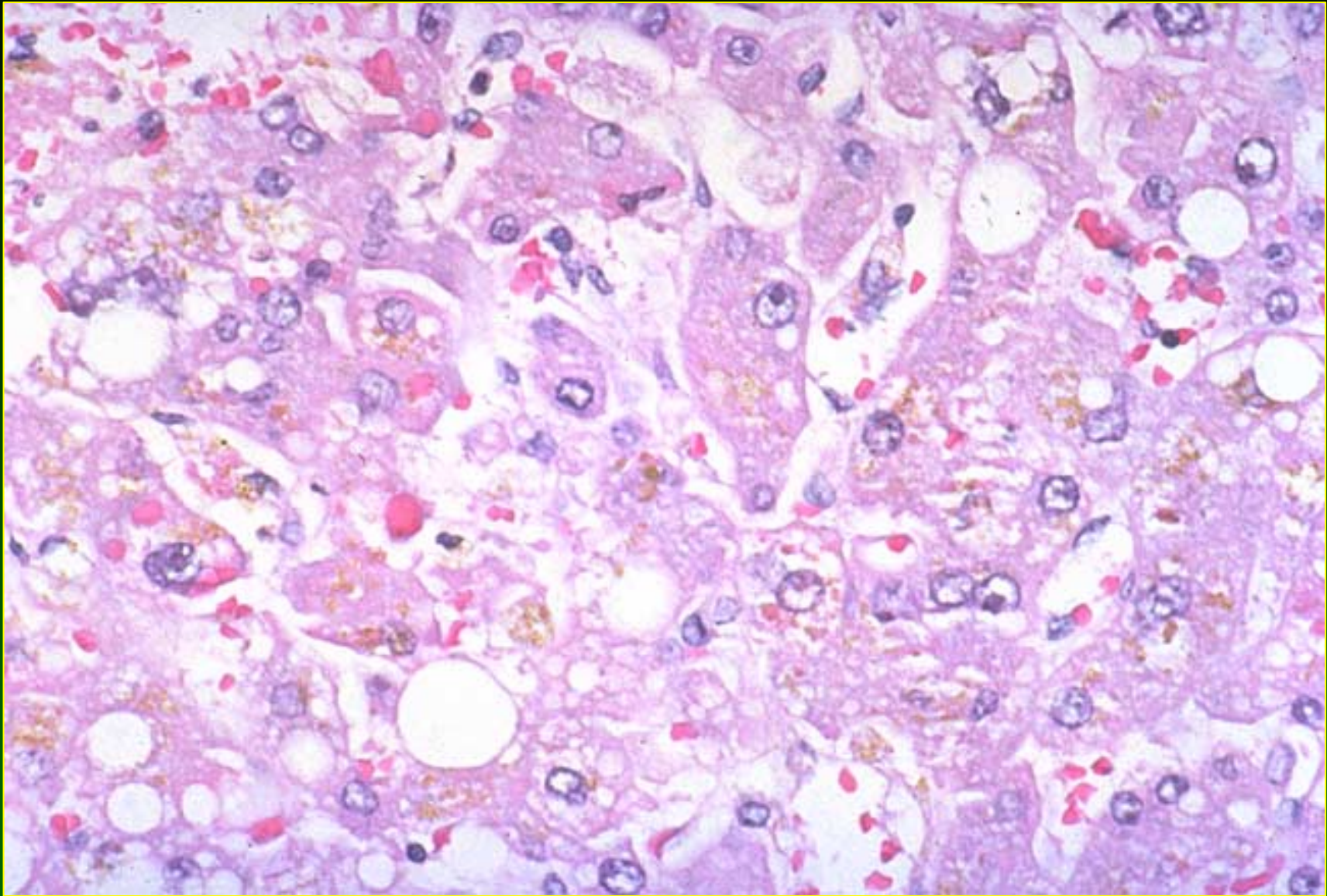


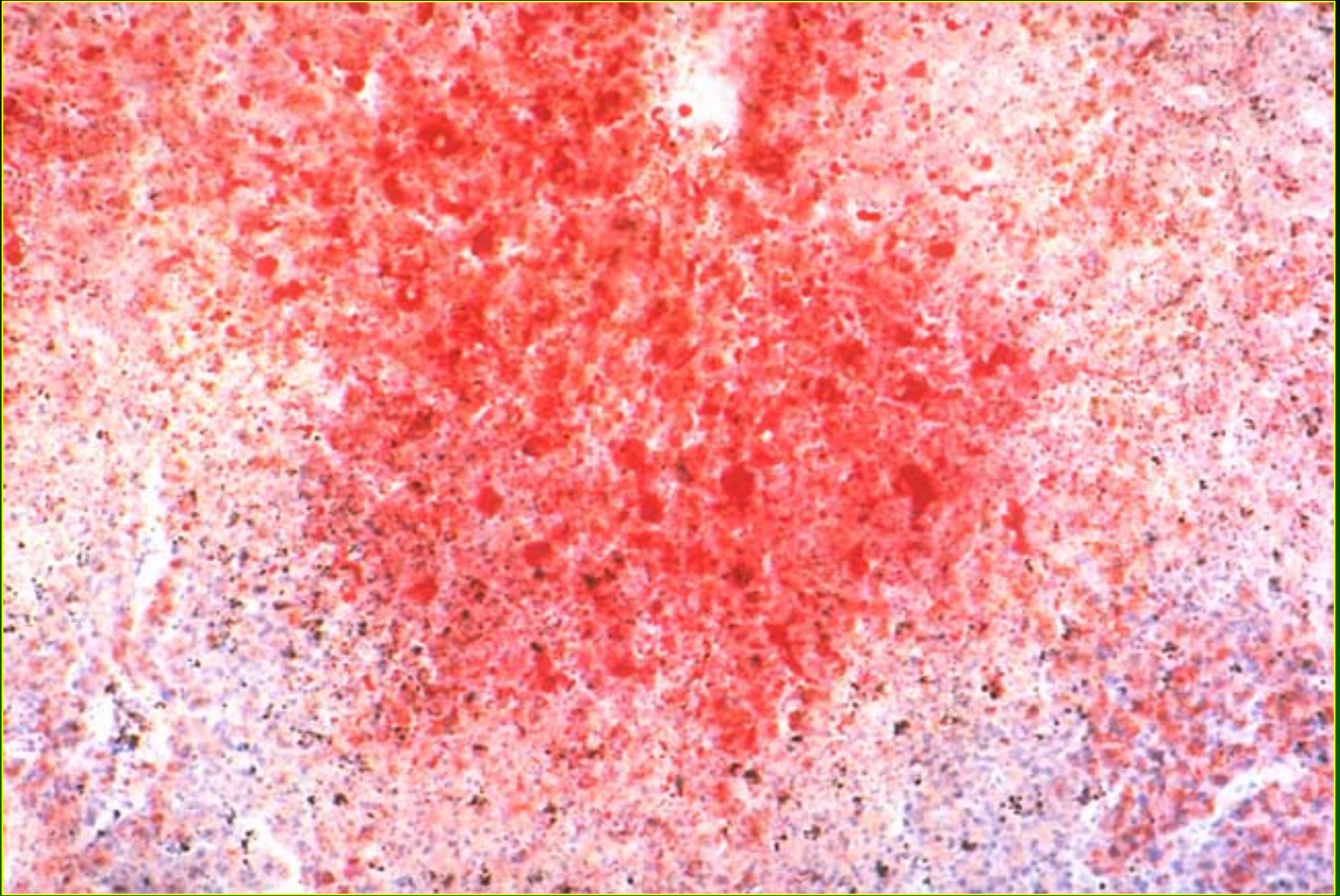
Hepatotoxicity of Metals

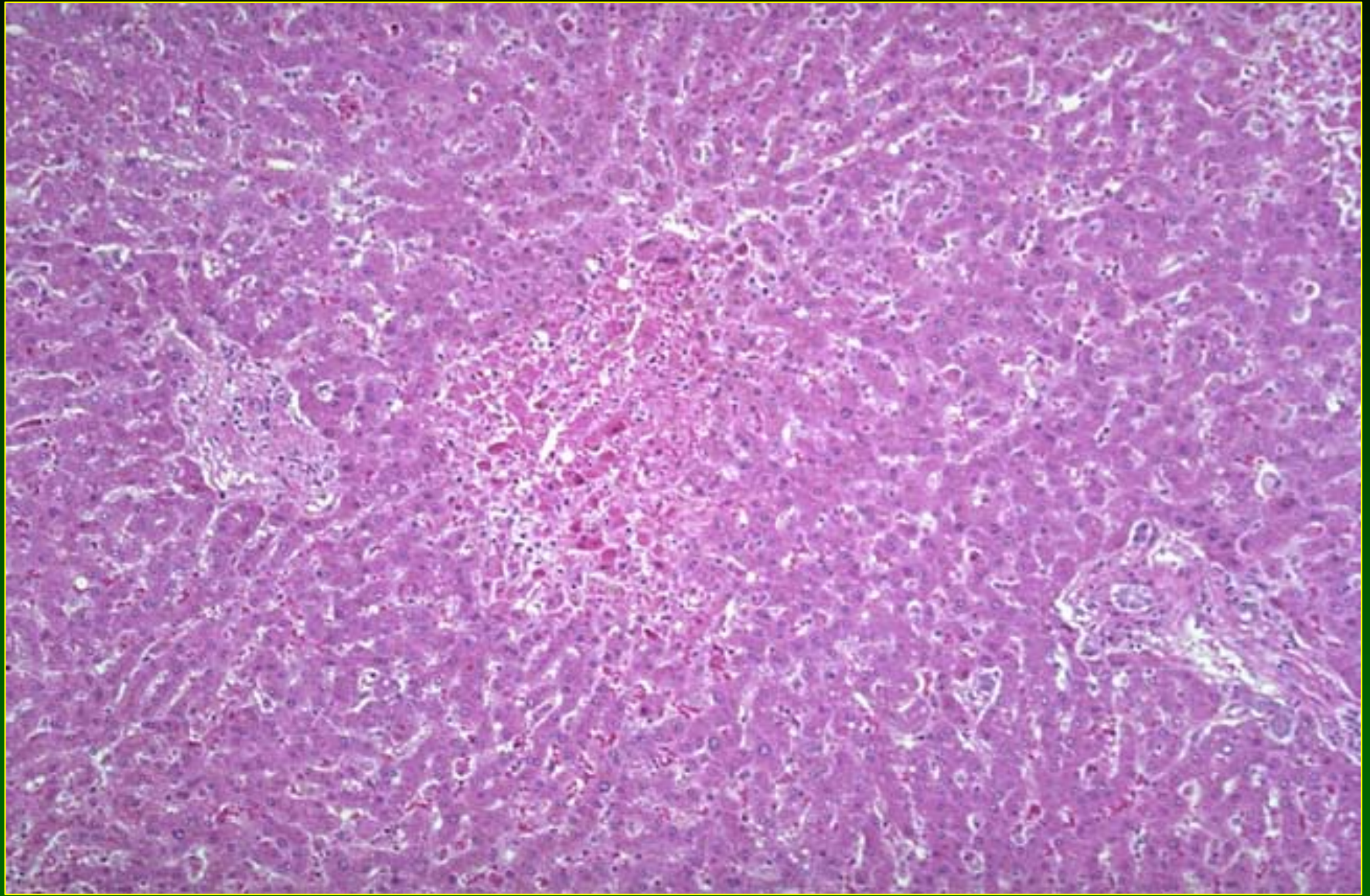
Copper (1)

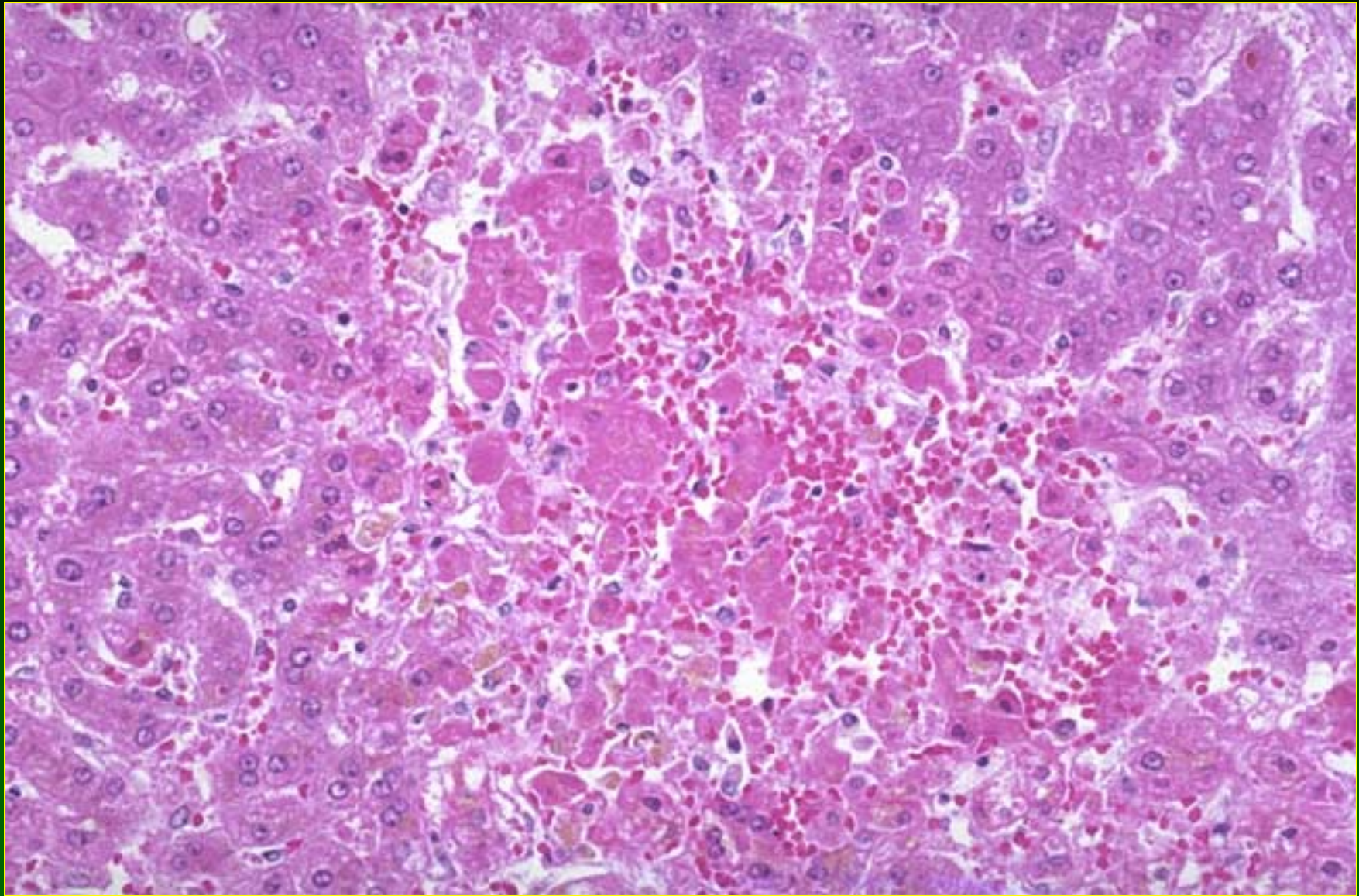
- Acute Toxicity: Zone 3 necrosis; cholestasis; hypertrophy of Kupffer cells with erythrophagocytosis; copper accumulation in Kupffer cells (sheep)

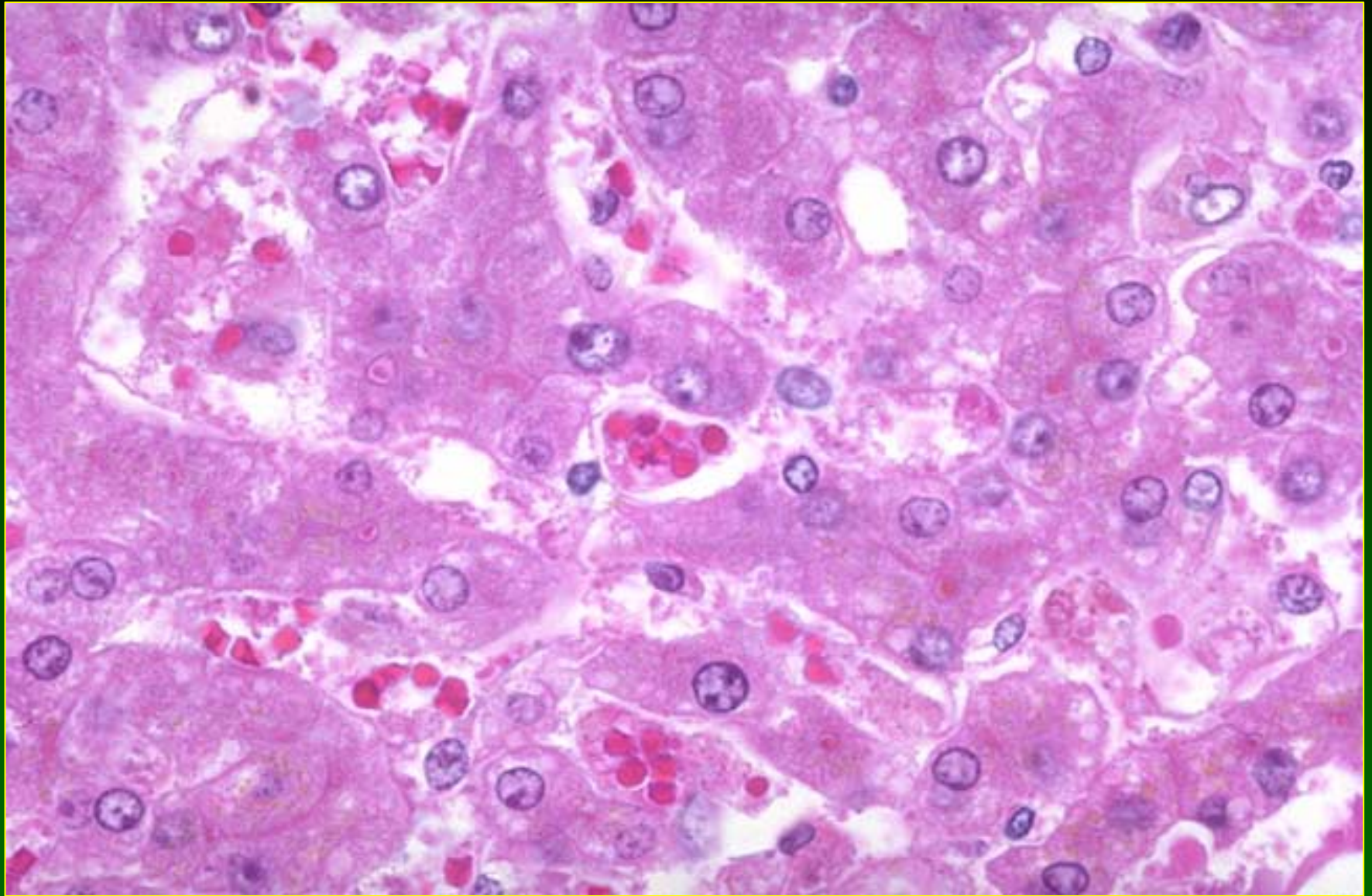
- A 44-year old woman with a history of having ingested a large amount of valium and alcohol. She was treated with Copper Sulfate to induce emesis. High levels of serum copper found and also high copper levels in liver tissue. Liver shows cholestasis and fat confirmed by Oil red o stain.







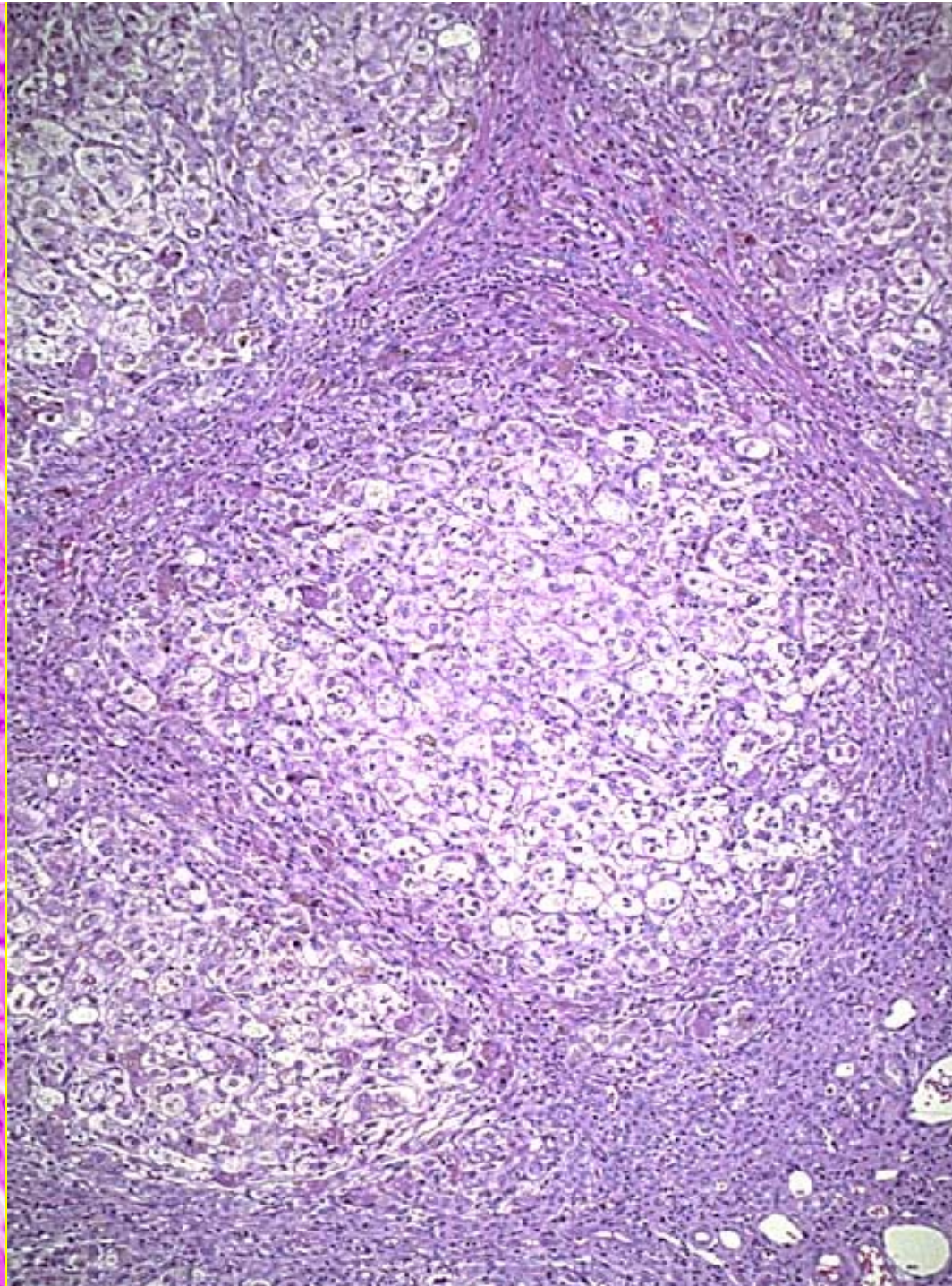
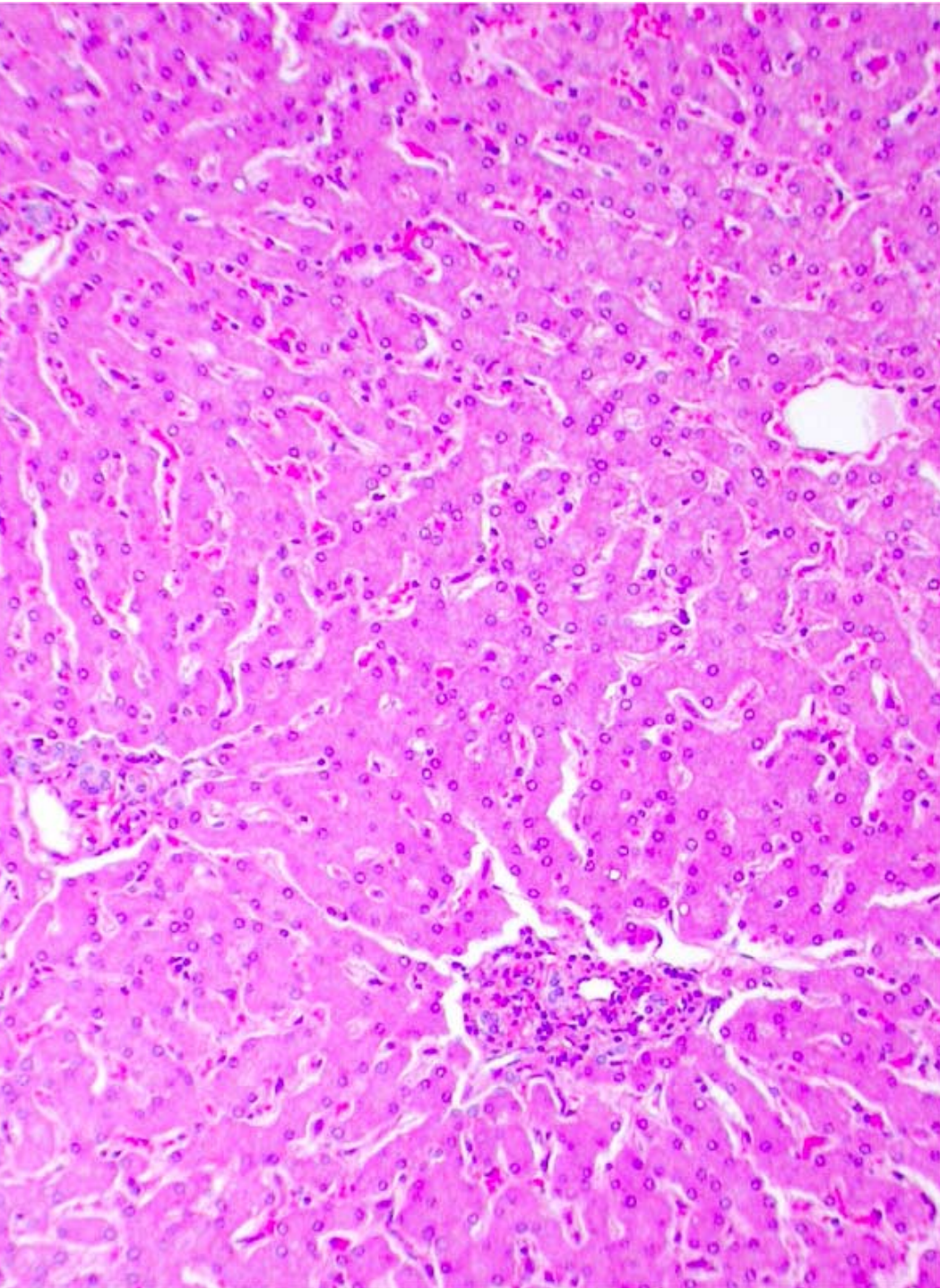


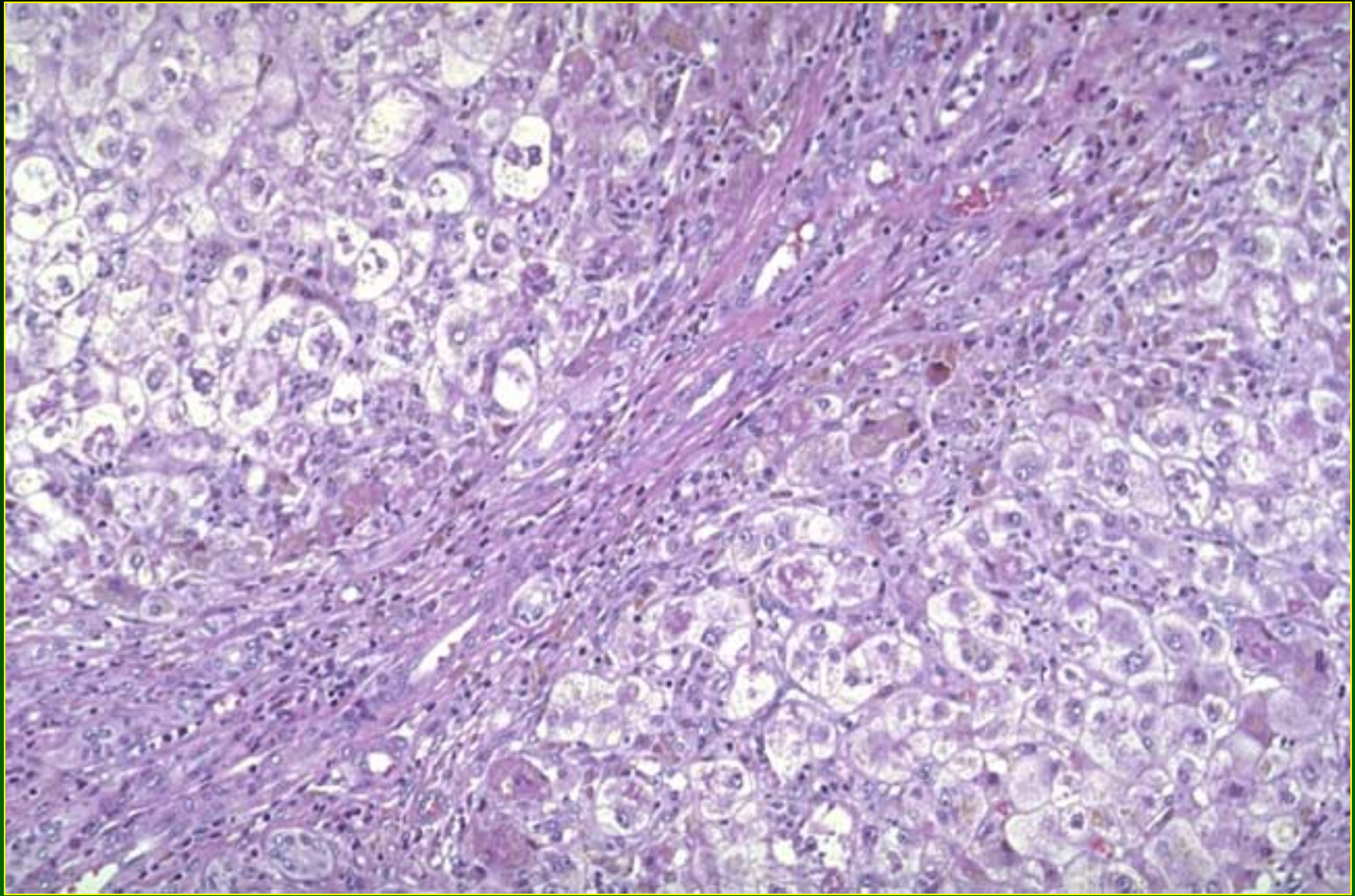


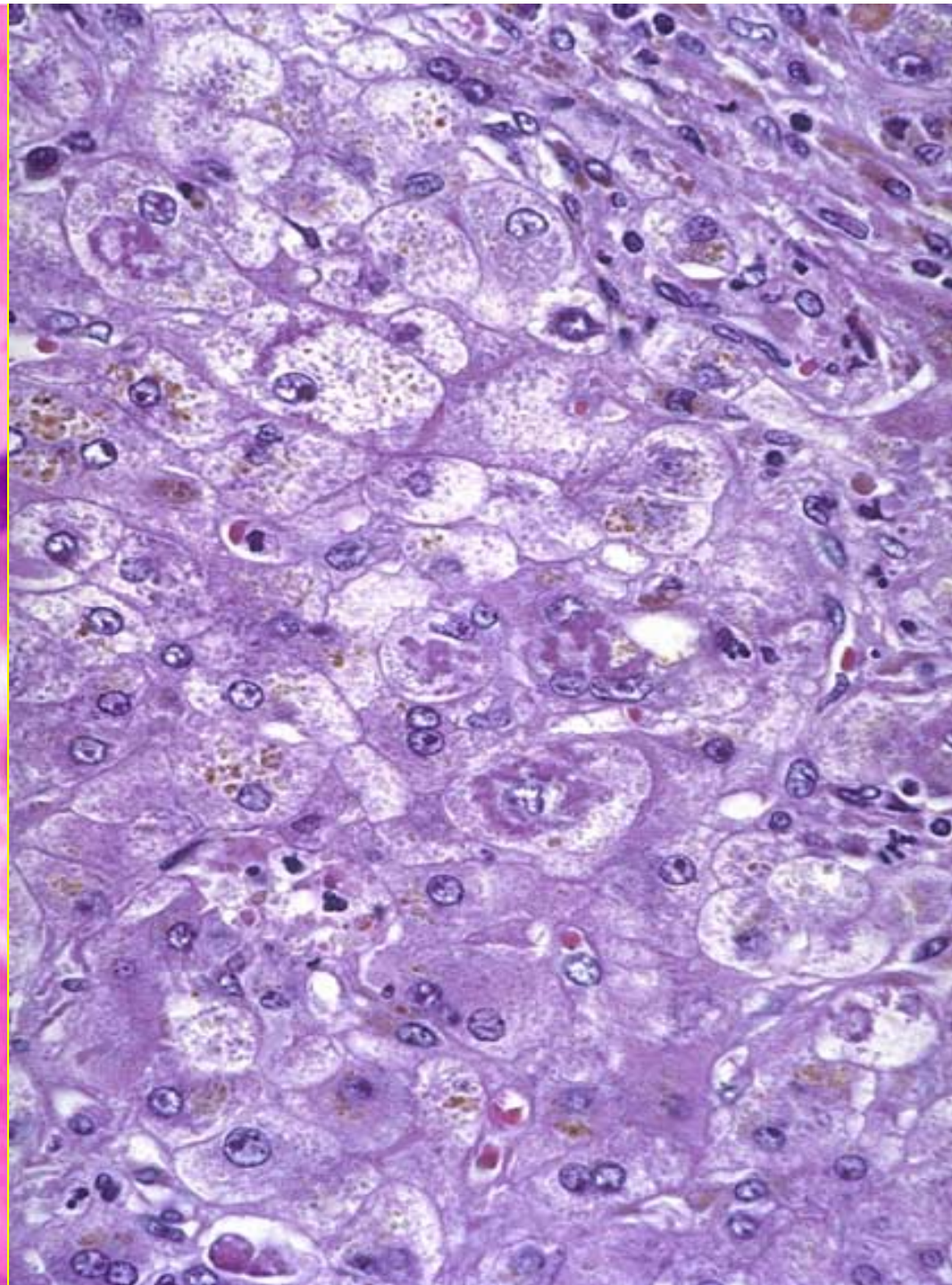
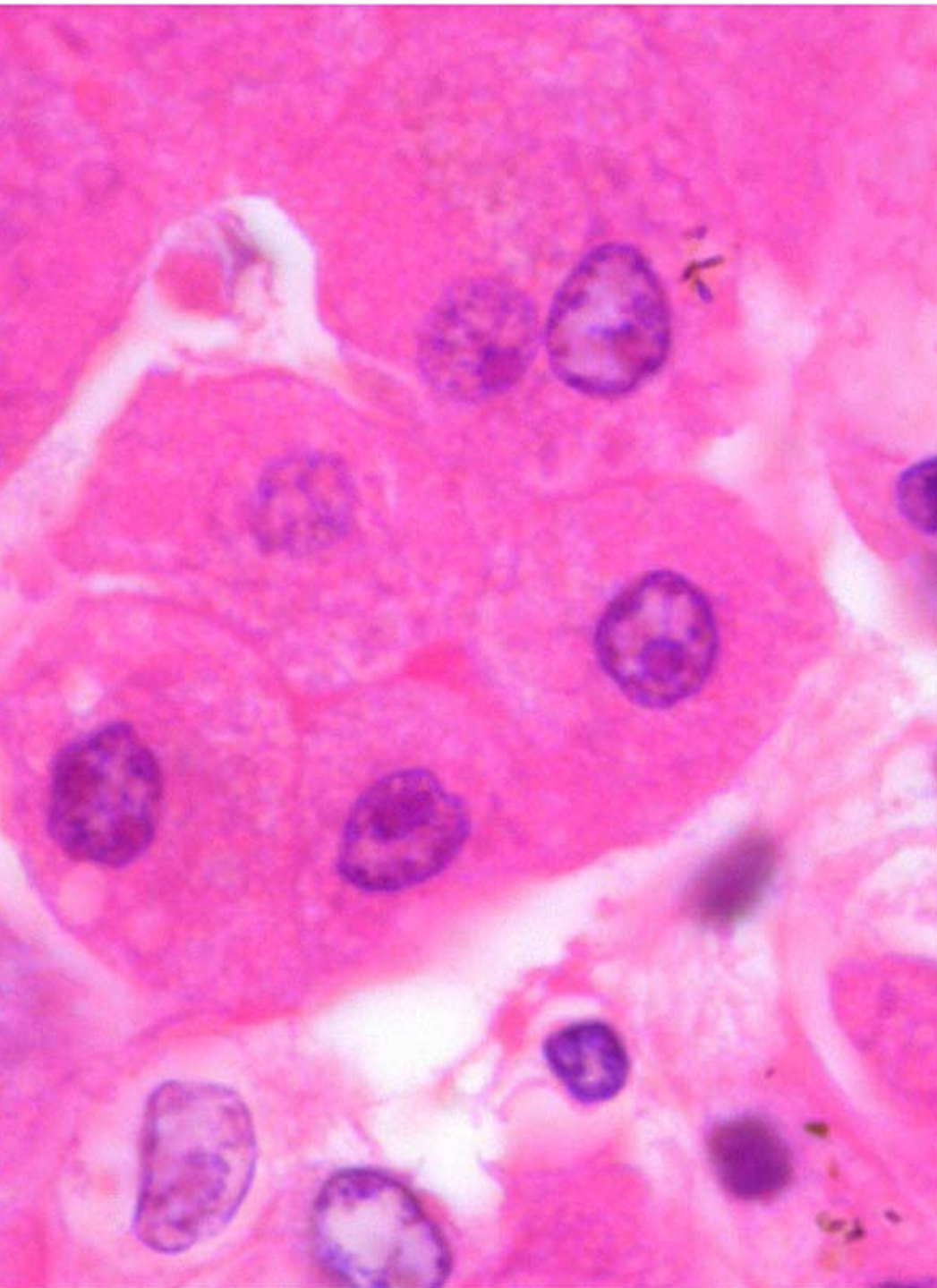Hepatotoxicity of Metals

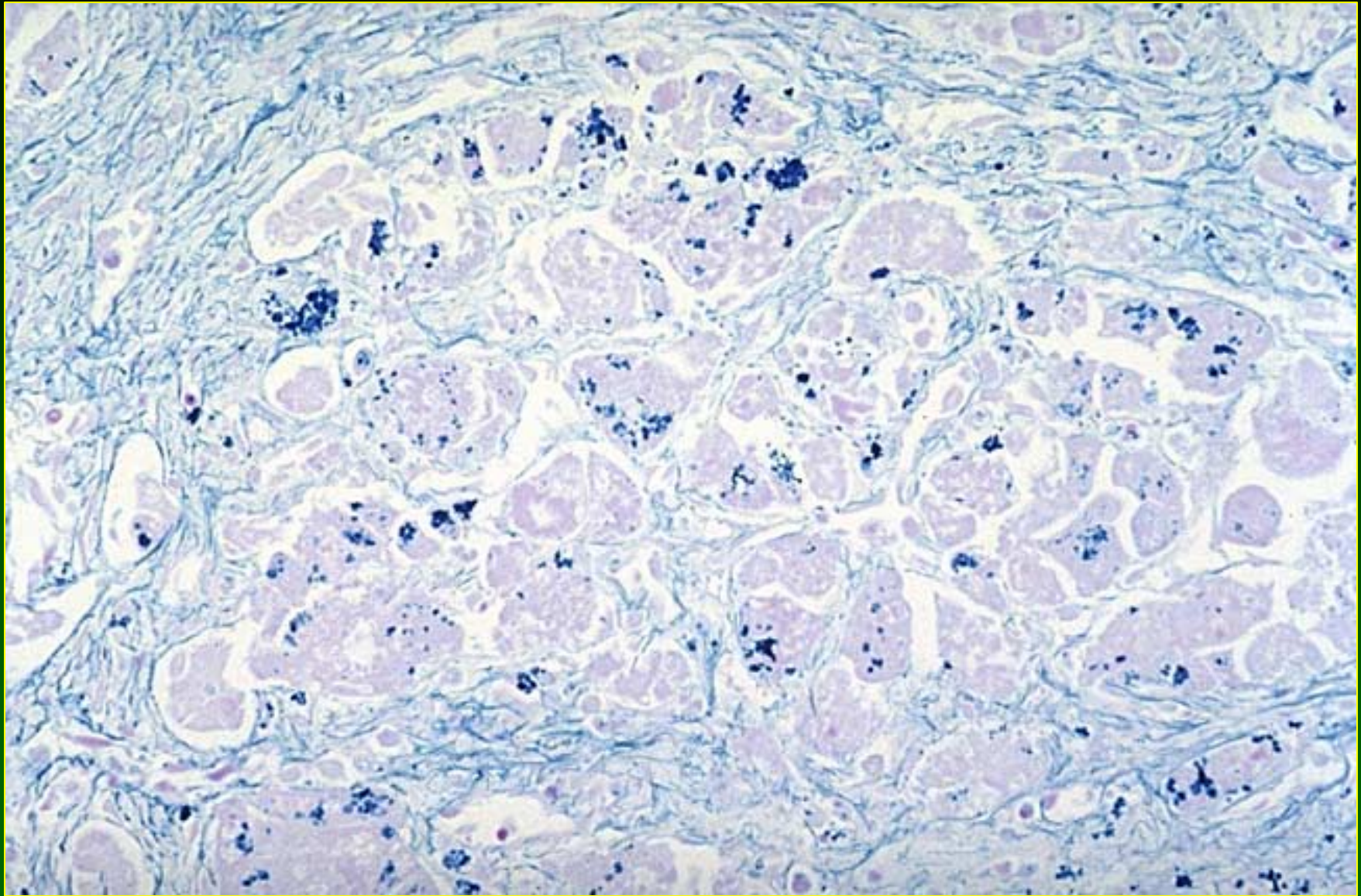
Copper (2)

- Chronic Toxicity:
 - Epithelioid granulomas
 - Cirrhosis with Mallory bodies resembling Indian childhood cirrhosis
 - Angiosarcoma









Iron Poisoning

General

- Leading cause of poisoning deaths in children < 6 years of age in U.S.
- > 110,000 reports to U.S. poison control centers since 1986
- 17% of children reported to poison control centers (1980-1992)

Iron Poisoning

General

- Rarely reported in adults*
- Fatalities can occur after as little as 400 mg elemental iron in children (600-5000mg in adults)

*Manoguerra: Am J Hosp Pharm 1976;33:1088-1090

Iron Poisoning

Elemental Iron Content of Products

Product	Elemental Iron
Ferrous sulfate 325 mg tablets	60
Ferrous gluconate 325 mg tablets	40
Ferrous fumarate 325 mg tablets	105
Prenatal vitamins with iron	40-60
Adults vitamins with iron	10-100
Children's vitamins	3-25

Stage of Iron Poisoning*

Stage	Onset	Symptoms
I	<6 hours	GI bleeding, vomiting diarrhea, shock, lethargy, coma
II	6-24 hours	Apparent improvement
III	12-24 hours	Metabolic acidosis, fever, leukocytosis, liver and renal failure
IV	Weeks	Intestinal scarring with possible obstruction

*After Manoguerra, 1976

Iron Poisoning

Diagnosis

- History
- Presence of tablets in vomitus or lavage fluid
- Abdominal radiography
- Serum Fe determination:
 - >500 ug/dl (severe poisoning)
 - <300 ug/dl (moderate/severe)

Iron Poisoning

Treatment

- Sodium bicarbonate (oral, lavage, enema)
- X-ray of abdomen to assess removal of tablets
- Serum iron determination
- I.V. fluids for shock and acidosis
- Deferoxamine
- Treatment of liver and/or renal failure

Iron Toxicity

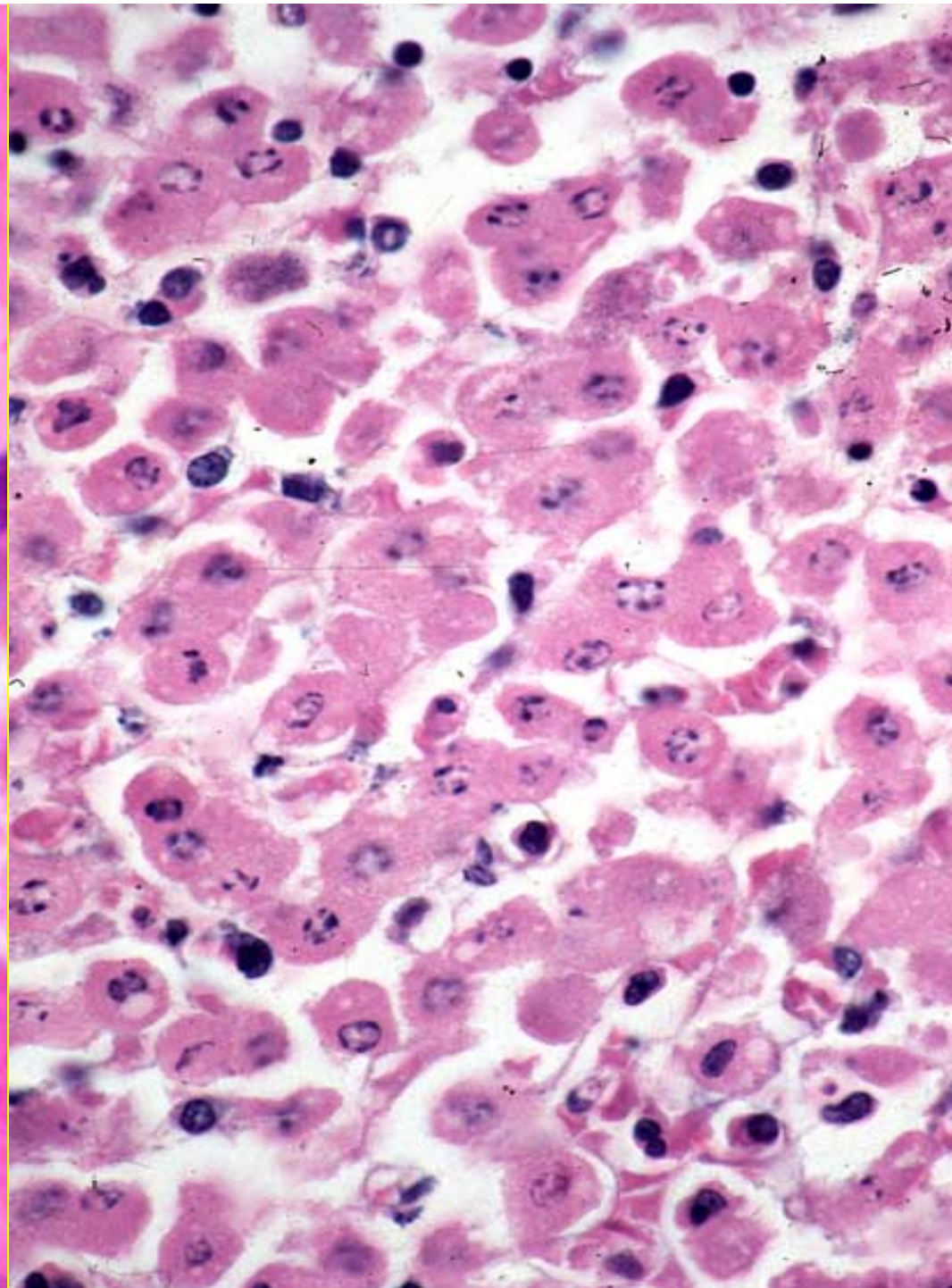
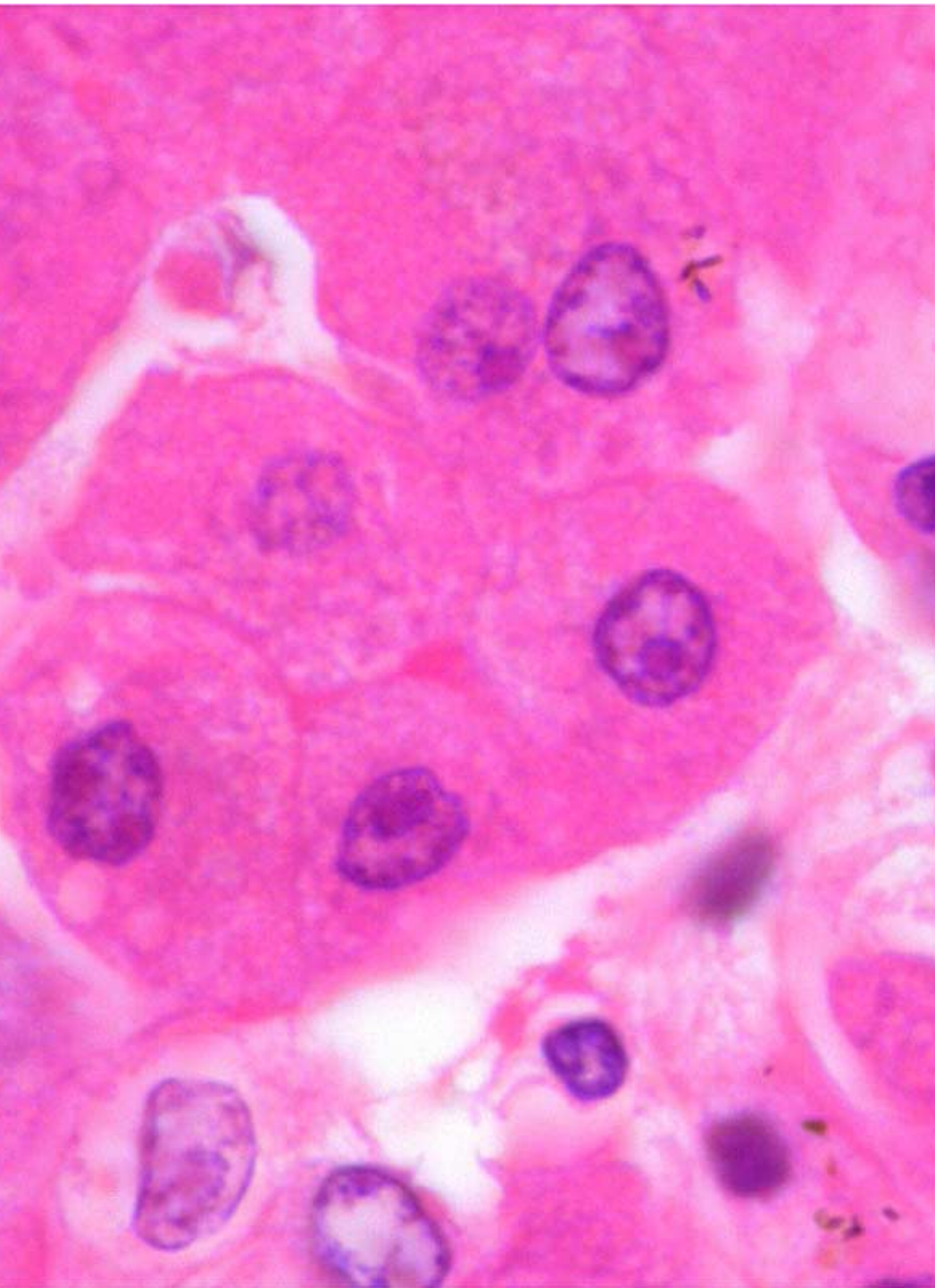
- Acute: Children > adults
- Acute/Subacute: Ulcers/strictures of esophagus or stomach caused by iron tablets in adults*

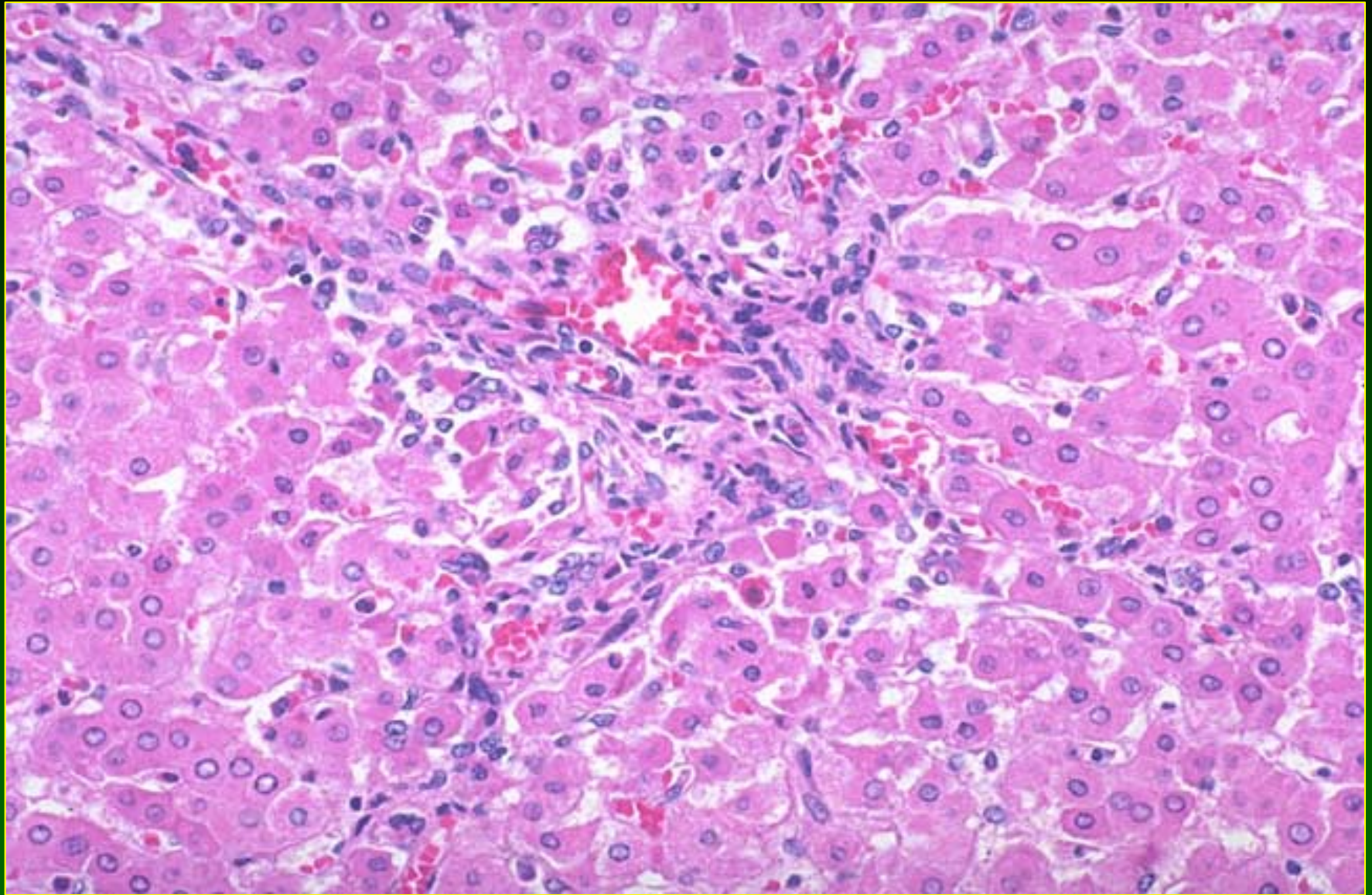
*Eckstein & Symons: Pathology 1996;28:142

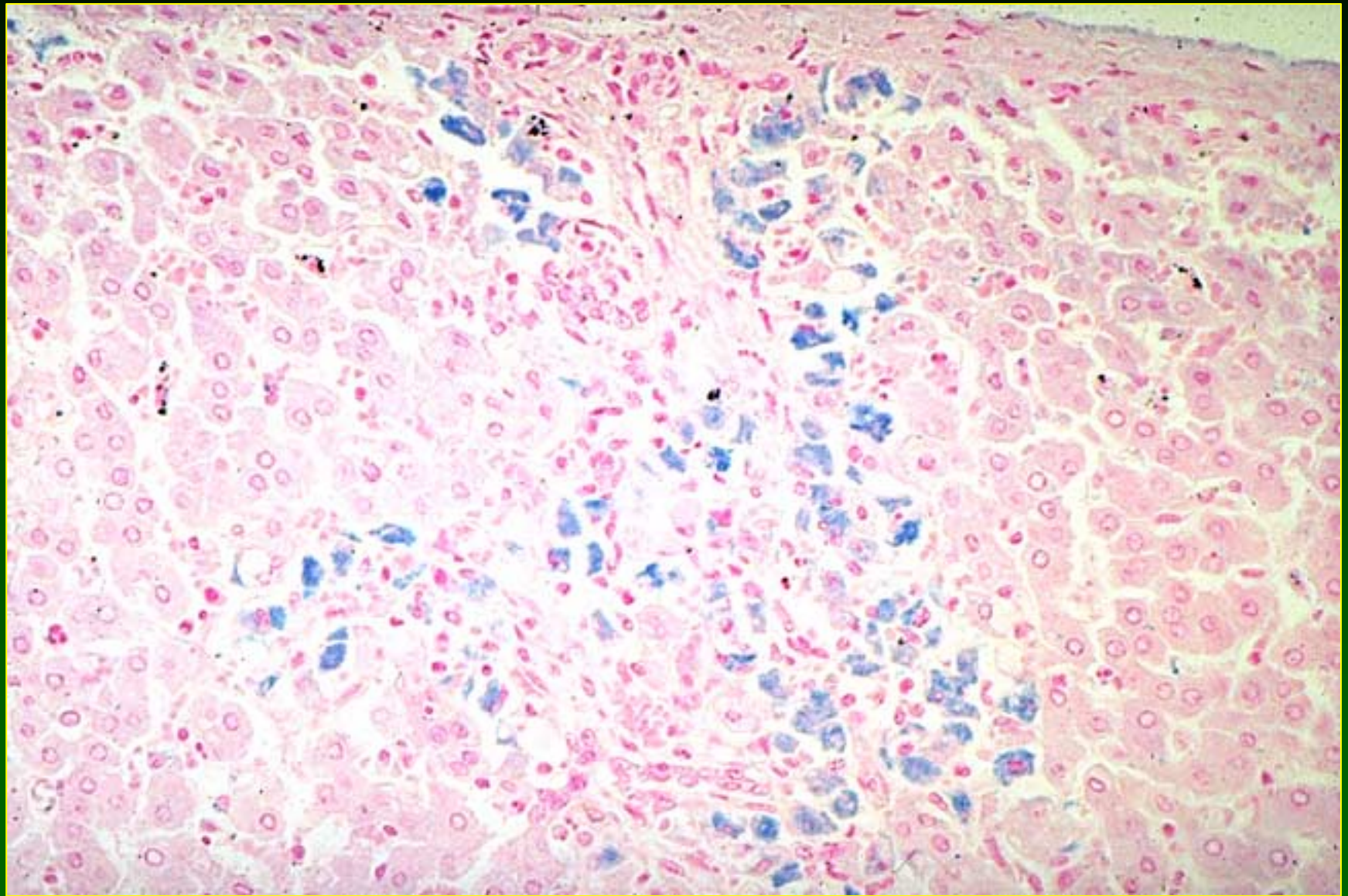
Iron Toxicity

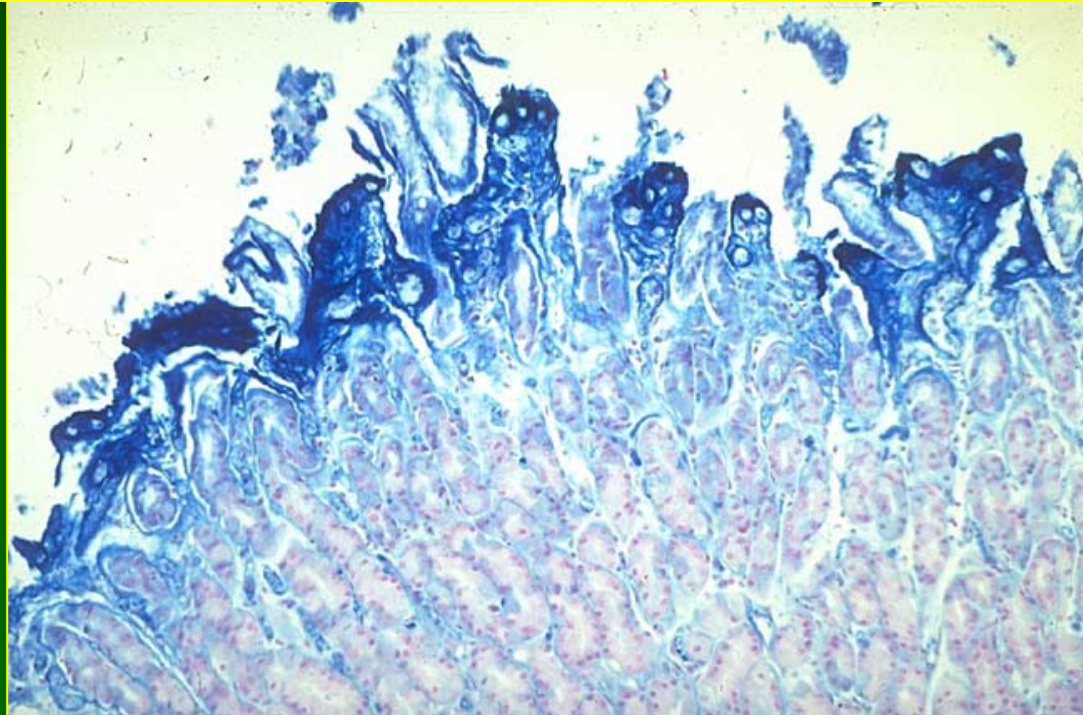
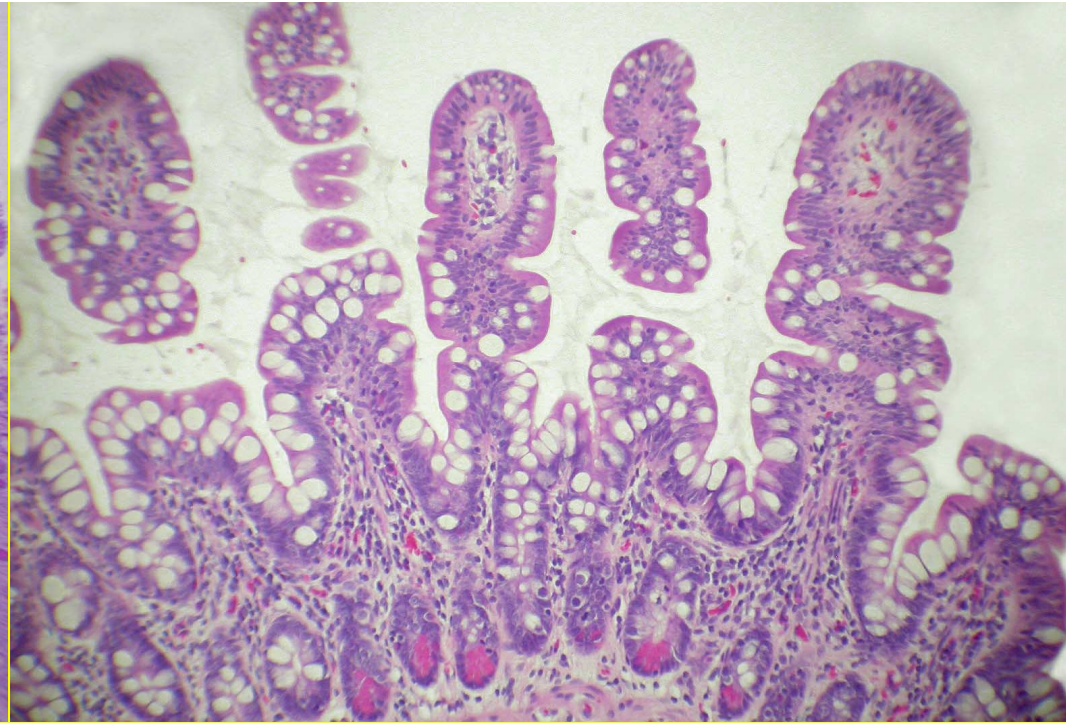
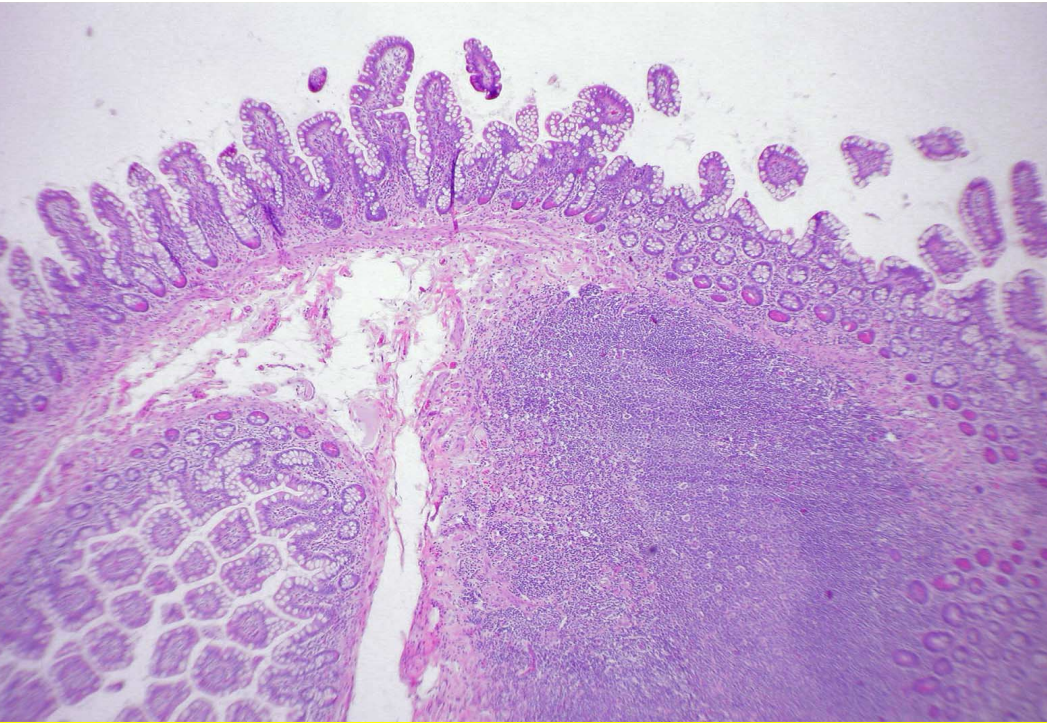
Pathology - Acute

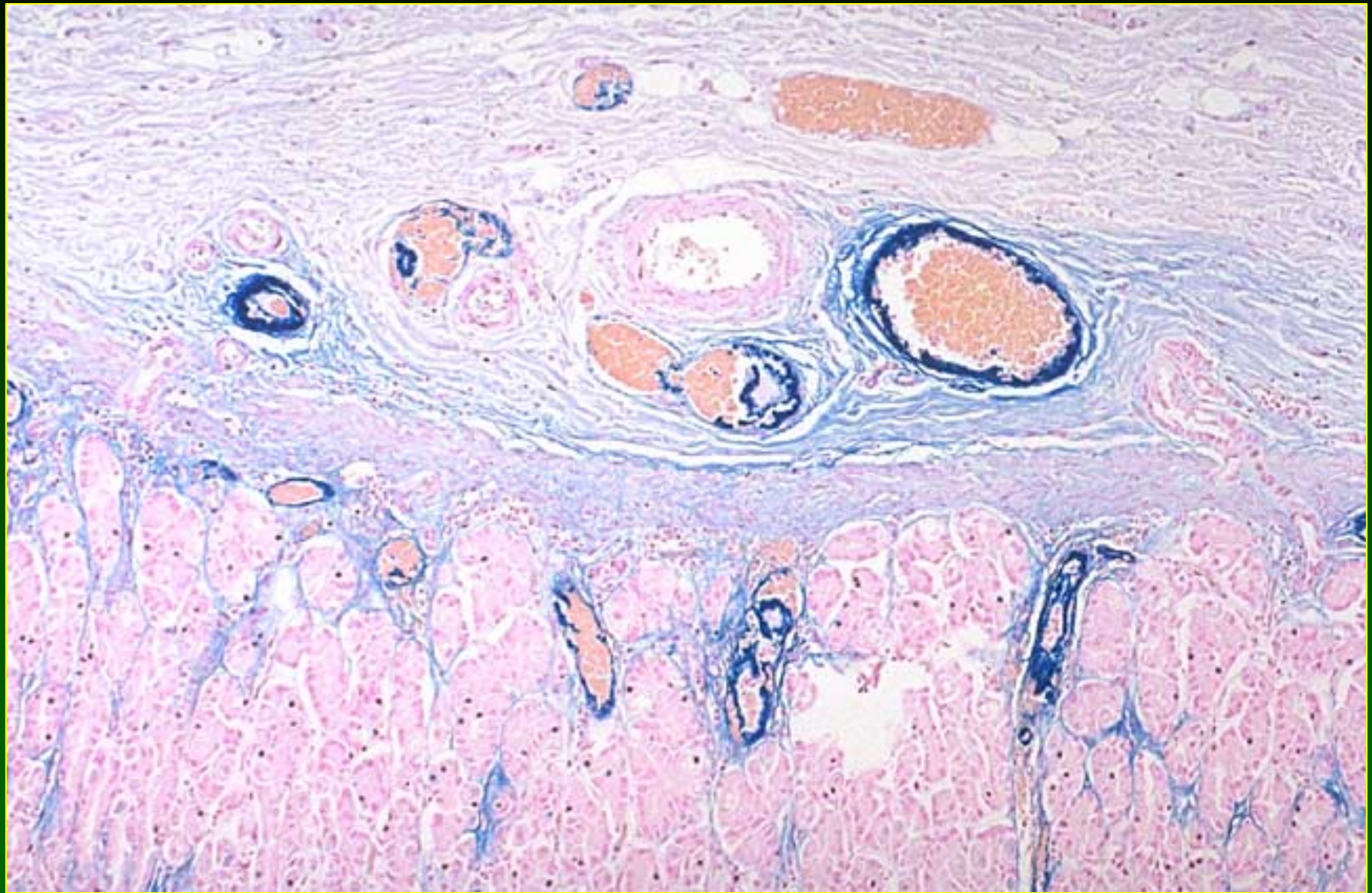
- Stomach/Intestine: Congestion, necrosis, neutrophilic infiltration, impregnation of mucosa and vessels with iron
- Liver; Zone 1 coagulative necrosis; iron impregnation of necrotic cells and sinusoidal endothelium

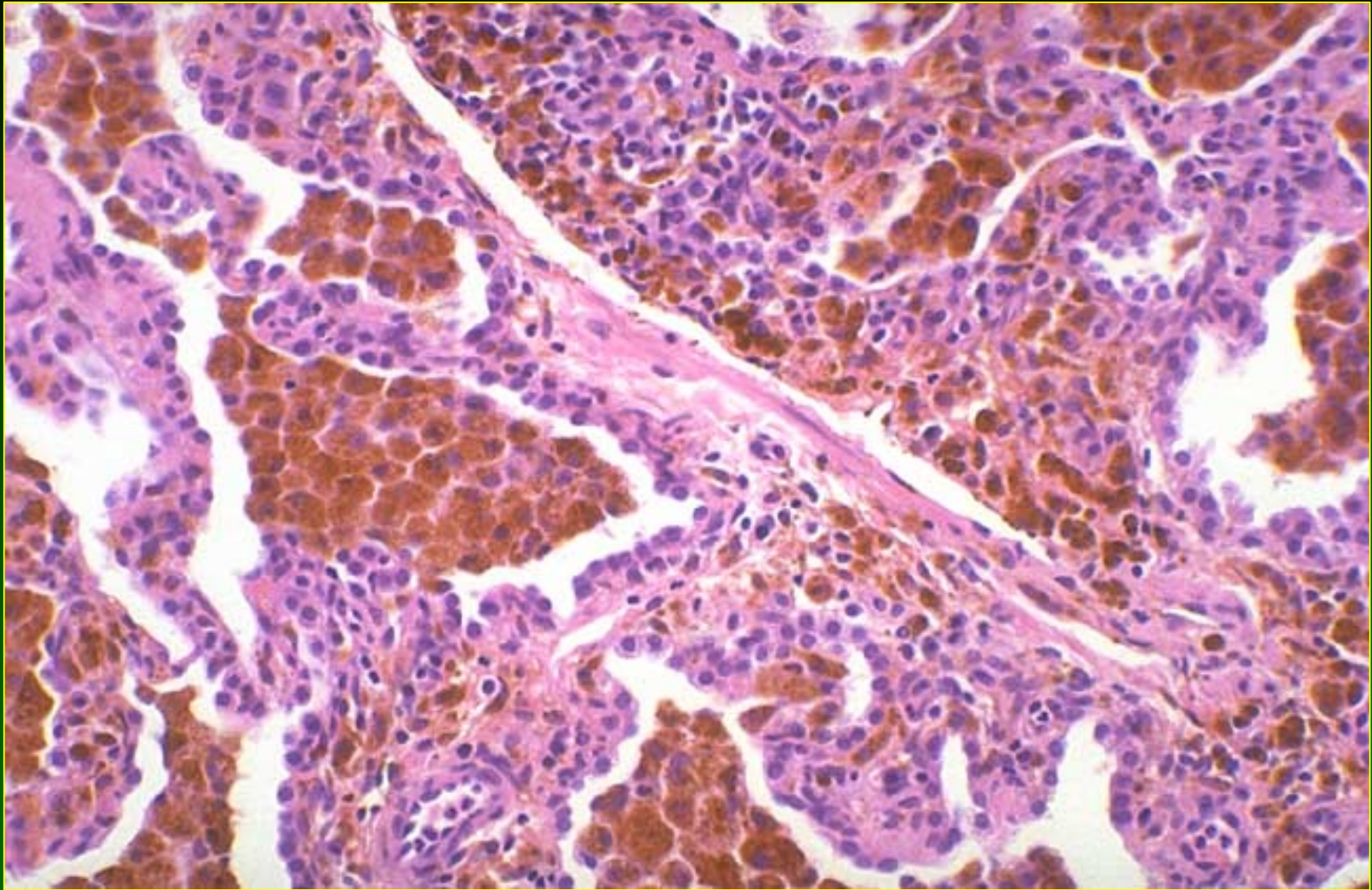


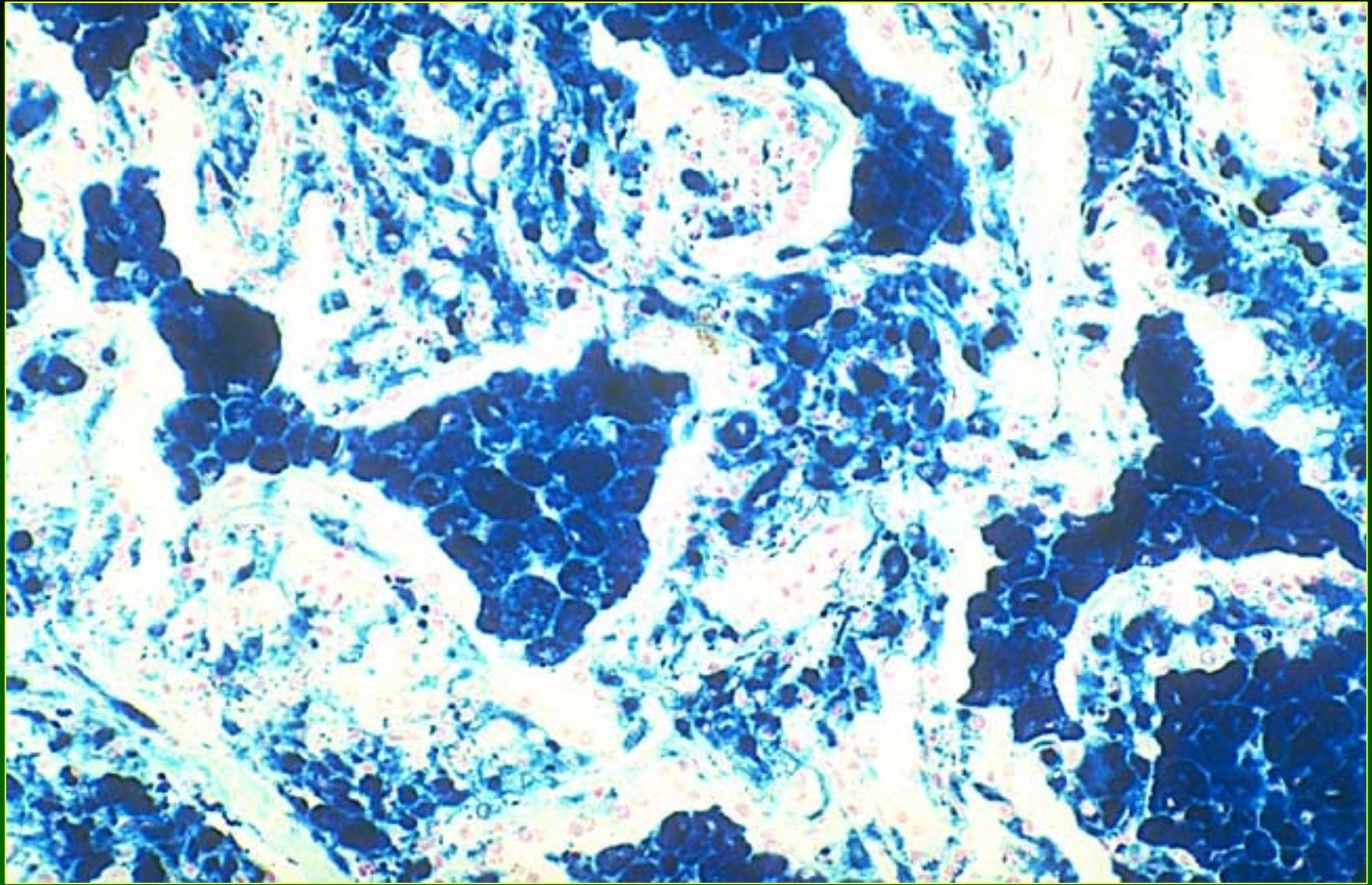












Iron Toxicity

Pathology - Chronic

- Hemosiderosis
- Fibrosis
- Cirrhosis - rarely

Iron Toxicity

Chronic

- Iron overload in children on prolonged parenteral nutrition
- Hemosiderosis in hemodialysis patients given parenteral iron
- Portacaval shunt hemosiderosis
- Hemosiderosis from chronic Fe ingestion
- Transfusional hemosiderosis

Hepatotoxicity of Metals

Acute Phosphorus Poisoning

- Accidental or suicidal ingestion of rodenticides, roach paste or fire crackers
- Minimum dose 15mg; lethal dose 60mg or more
- Mortality rate 27% and 48% in two series

Hepatotoxicity of Metals

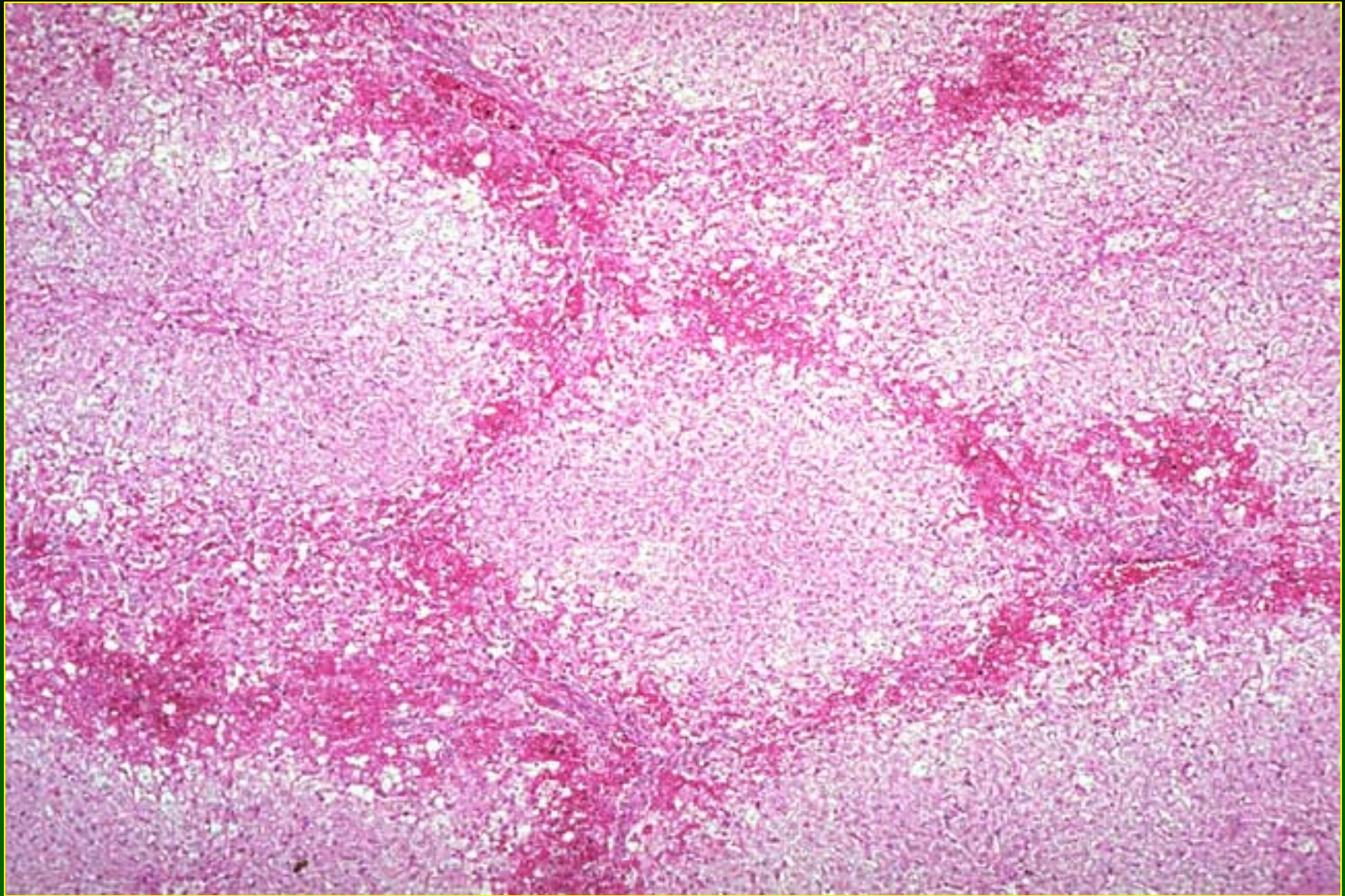
Acute Phosphorus Poisoning

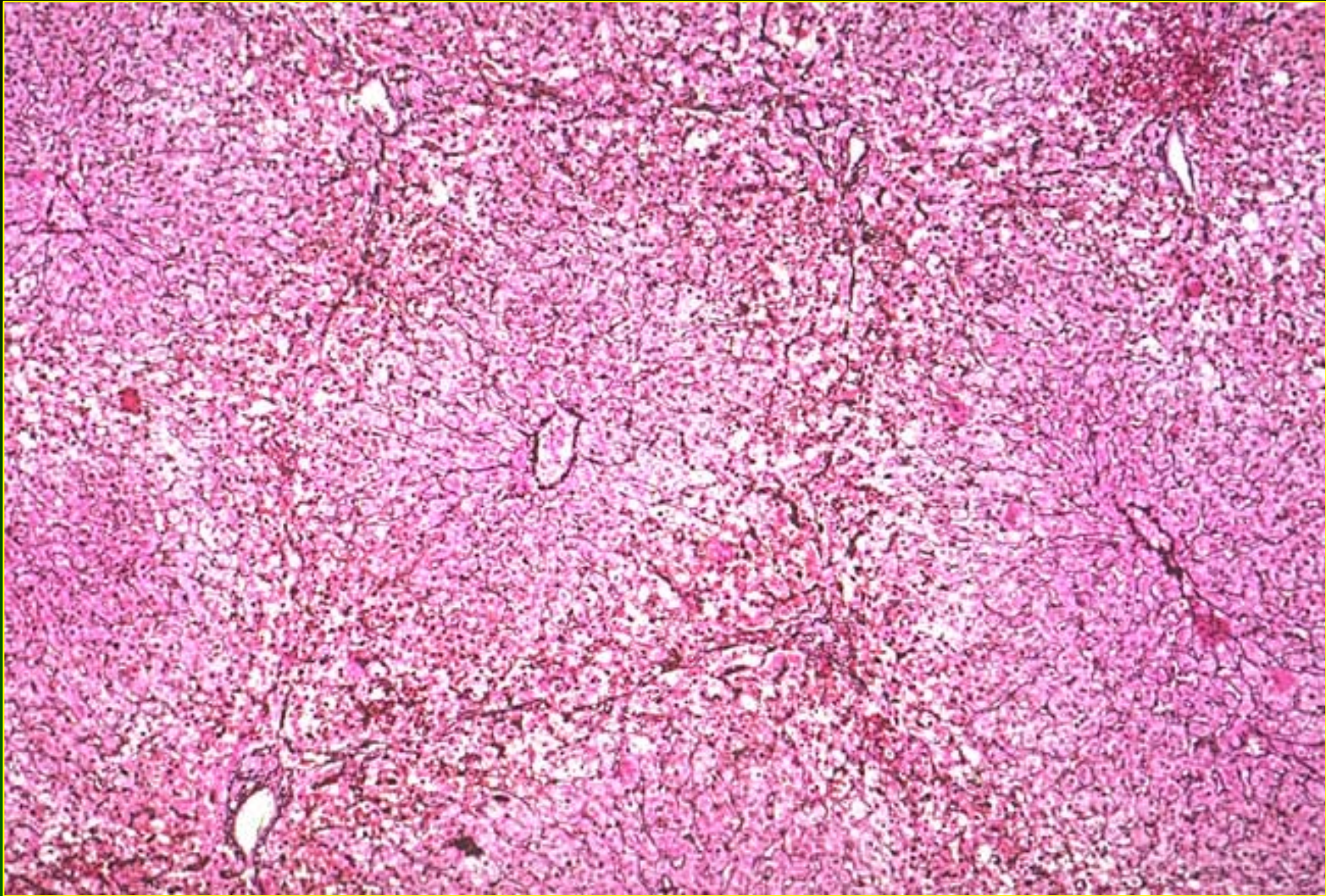
- Cutaneous burns, garlic odor and luminescence of vomitus or feces
- 6-8 hours: Nausea, vomiting, diarrhea, abdominal pain
- 1-3 Days: Symptom-free period
- > 3 Days: Same as first stage + hematemesis, hepatomegaly, jaundice, multiorgan failure and death

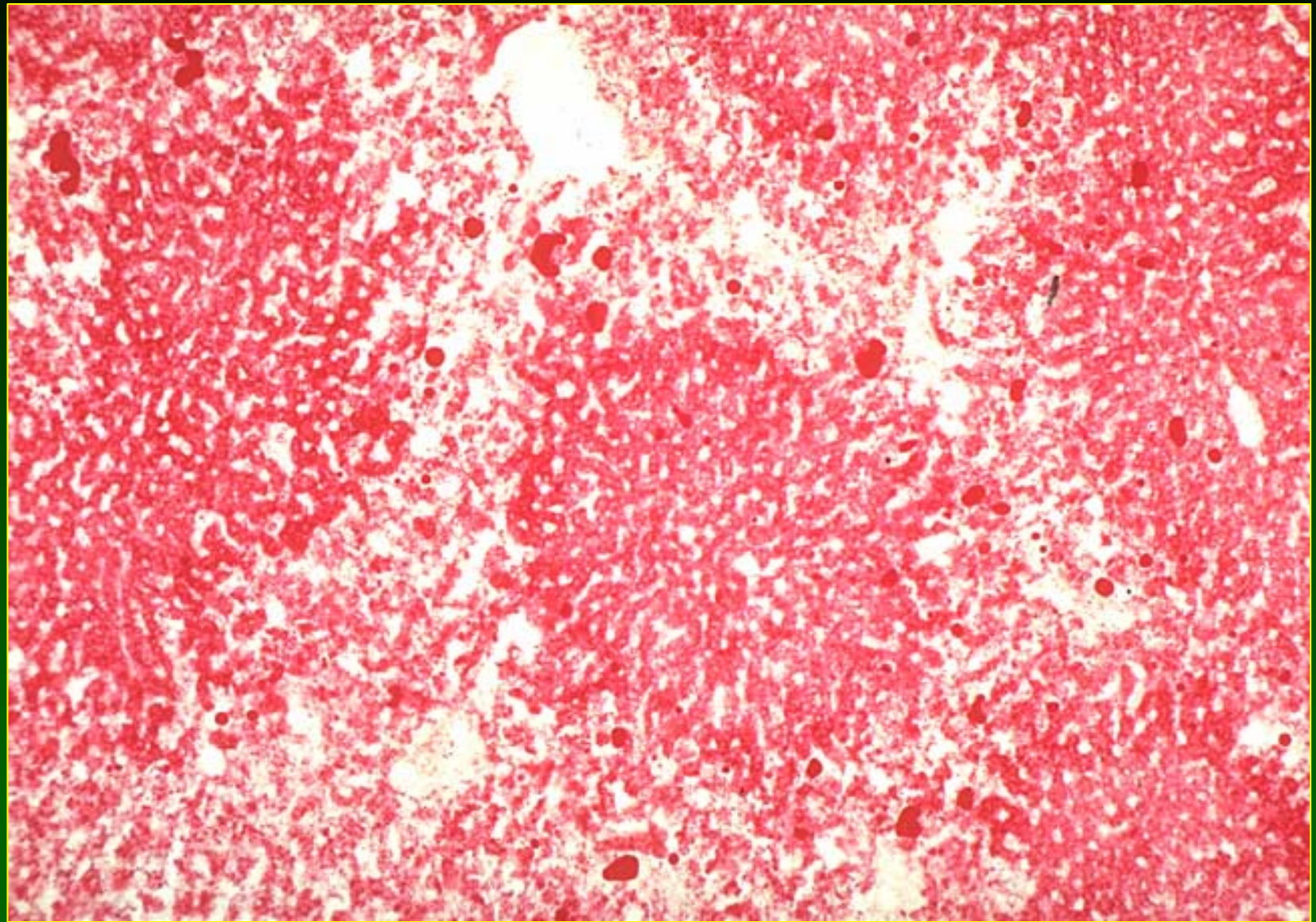
Hepatotoxicity of Metals

Phosphorus

- Acute Toxicity: Zone 1 necrosis +/- microvesicular steatosis; massive necrosis rare
- Chronic Toxicity: None







Hepatotoxicity of Metals

Thorium (1)

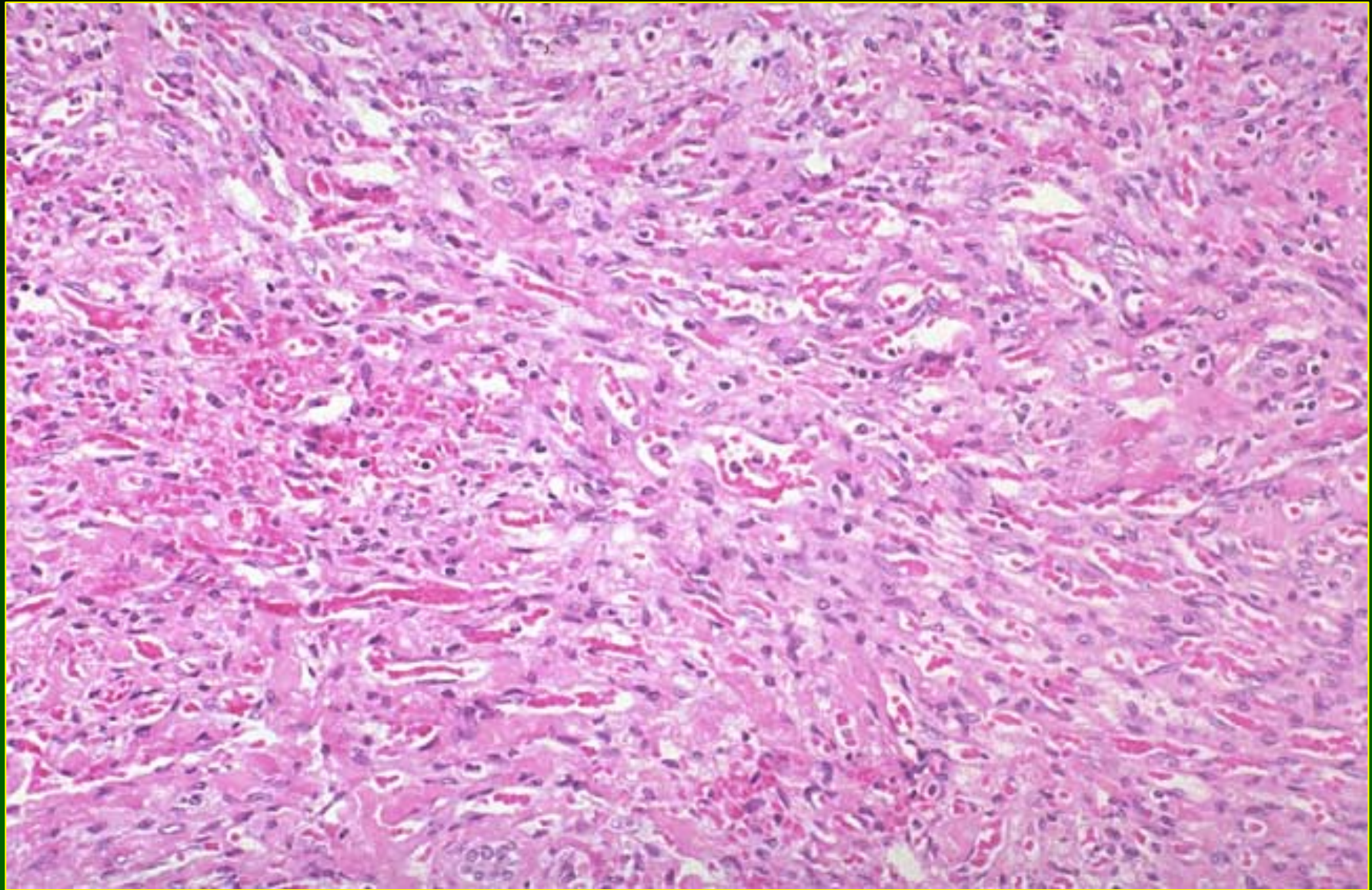
- Thorotrast, a colloidal suspension of thorium dioxide was used for radiographic opacification in 30s-50s
- Injected material accumulated in reticuloendothelial cells of the liver, spleen lymph nodes and bone marrow
- Half life: 400 years

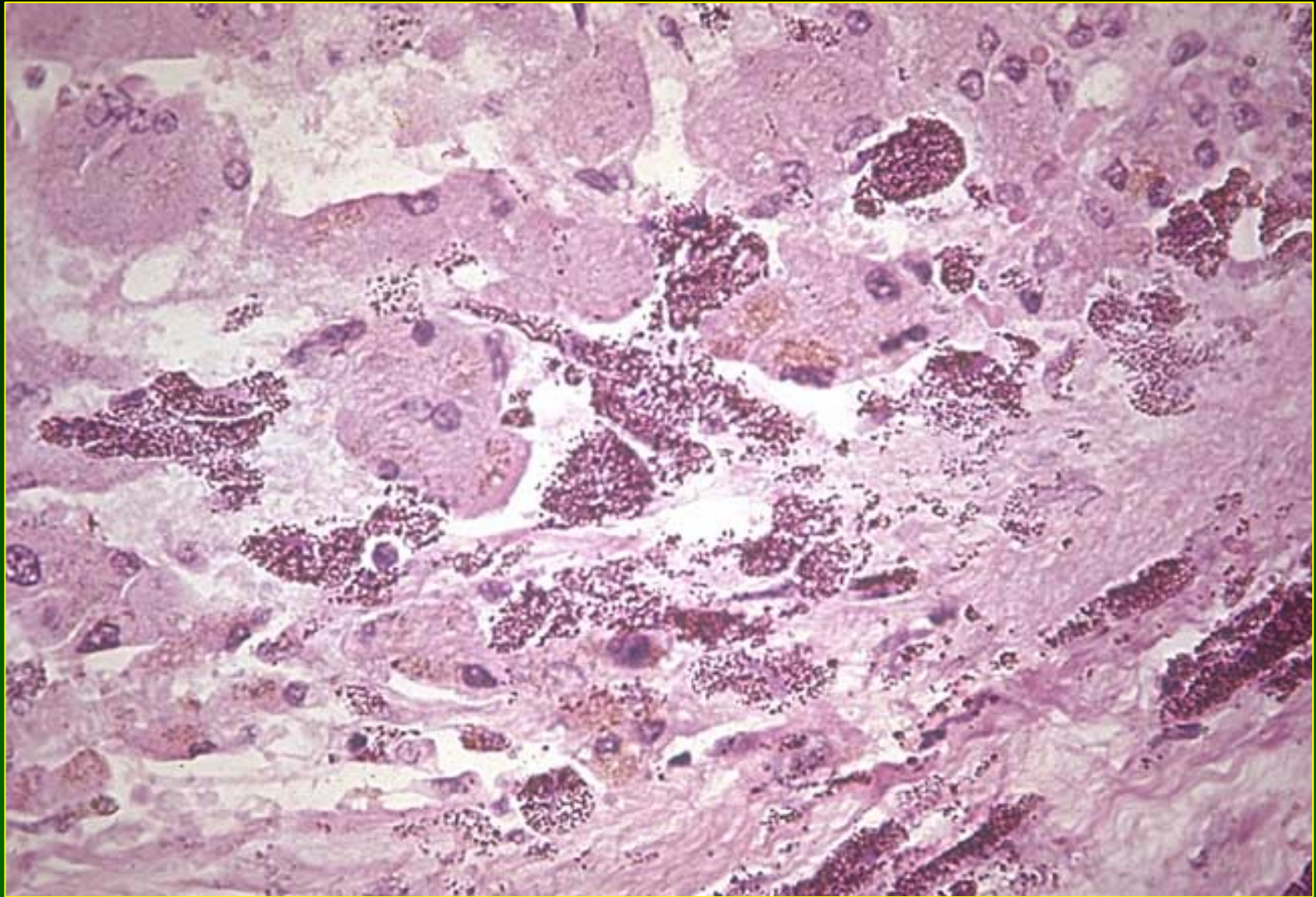
Hepatotoxicity of Metals

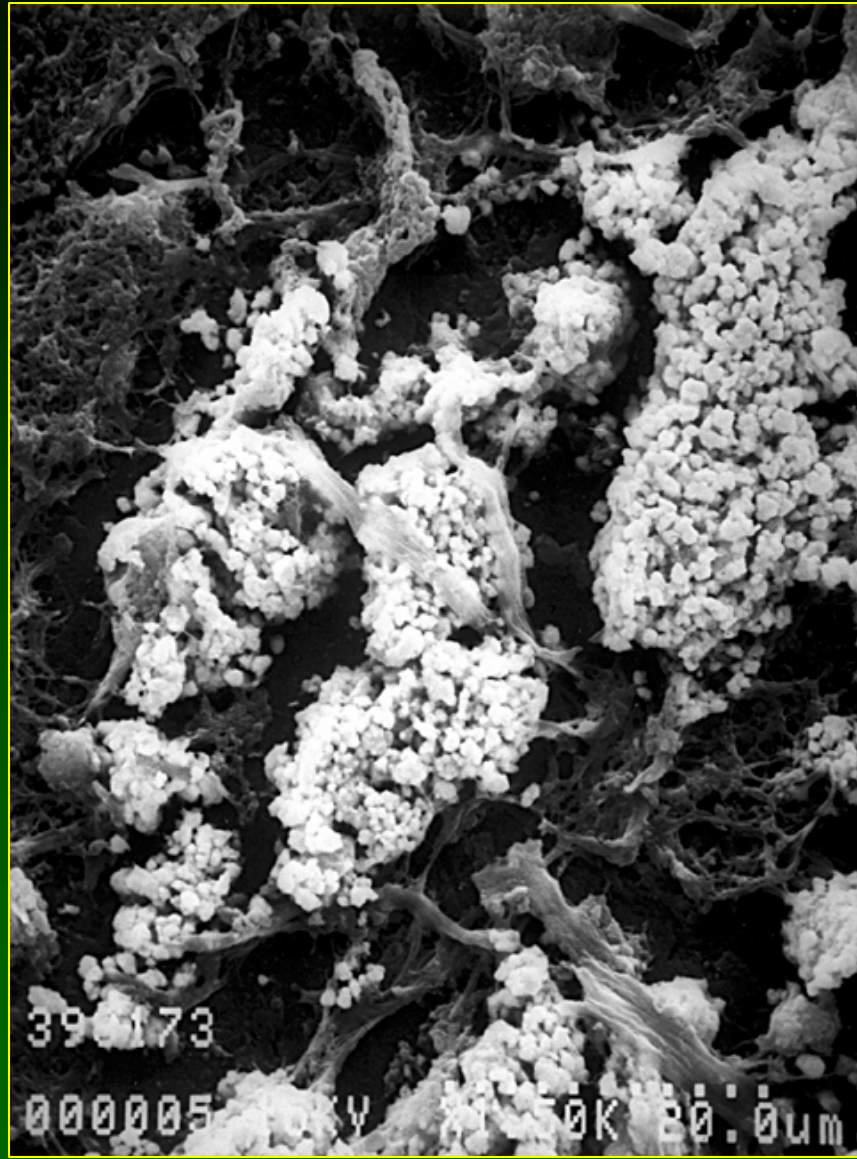
Thorium (2)

- Extensive fibrosis associated with Thorotrast deposits; cirrhosis (very rare)
- Venocclusive disease, granulomas (rare)
- Major complication is induction of malignant tumors--angiosarcoma, cholangiocarcinoma, hepatocellular carcinoma (latent period > 14 years)

- A 54 year old white male with right upper quadrant pain of two months duration. Sixteen years earlier the patient received 75cc of 2 1/2% thorium dioxide IV and radiographs of liver and spleen were made.







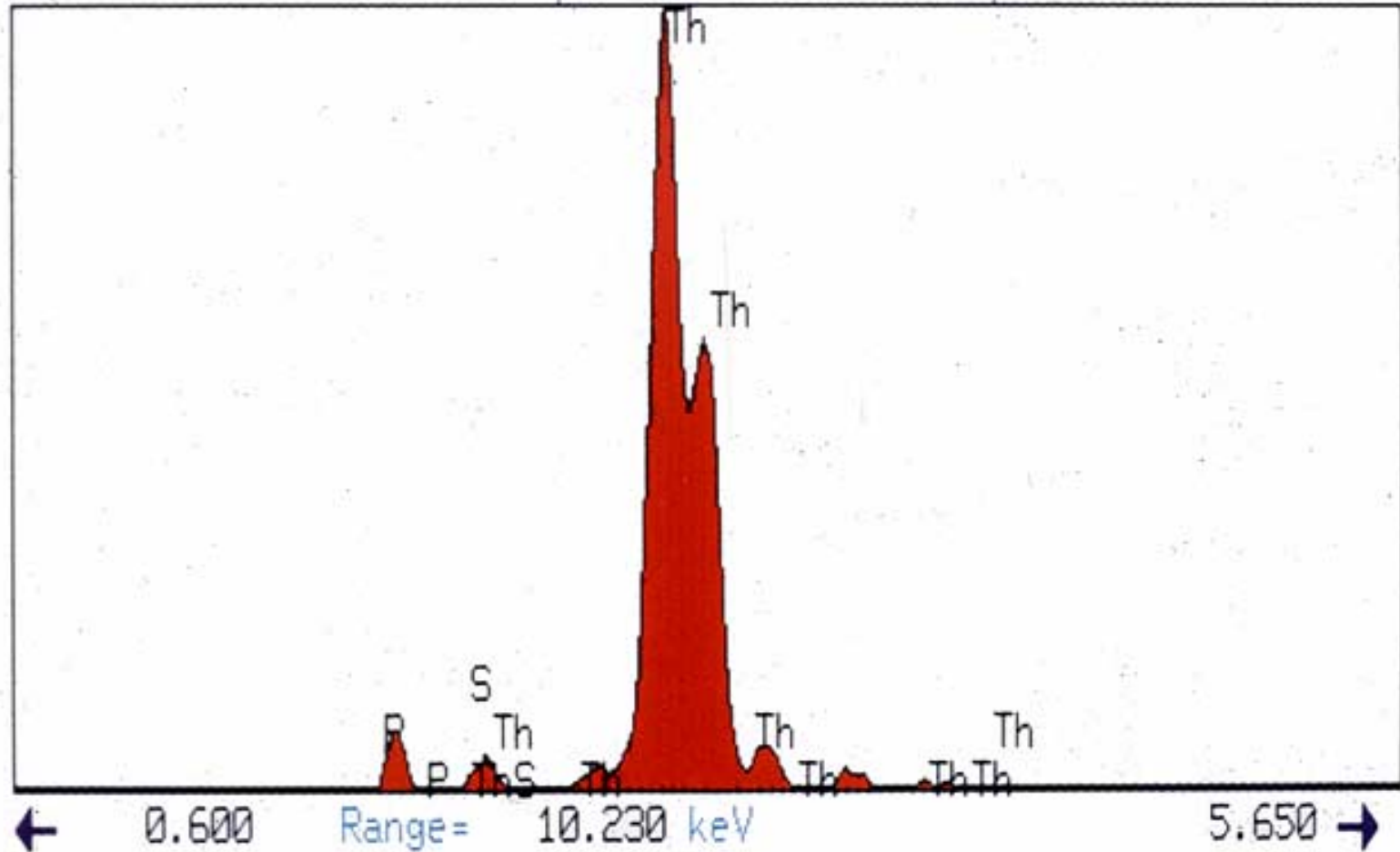
29-Jan-1988 14:10:40

1155546

Vert= 667 counts Disp= 1

Preset= 100 secs

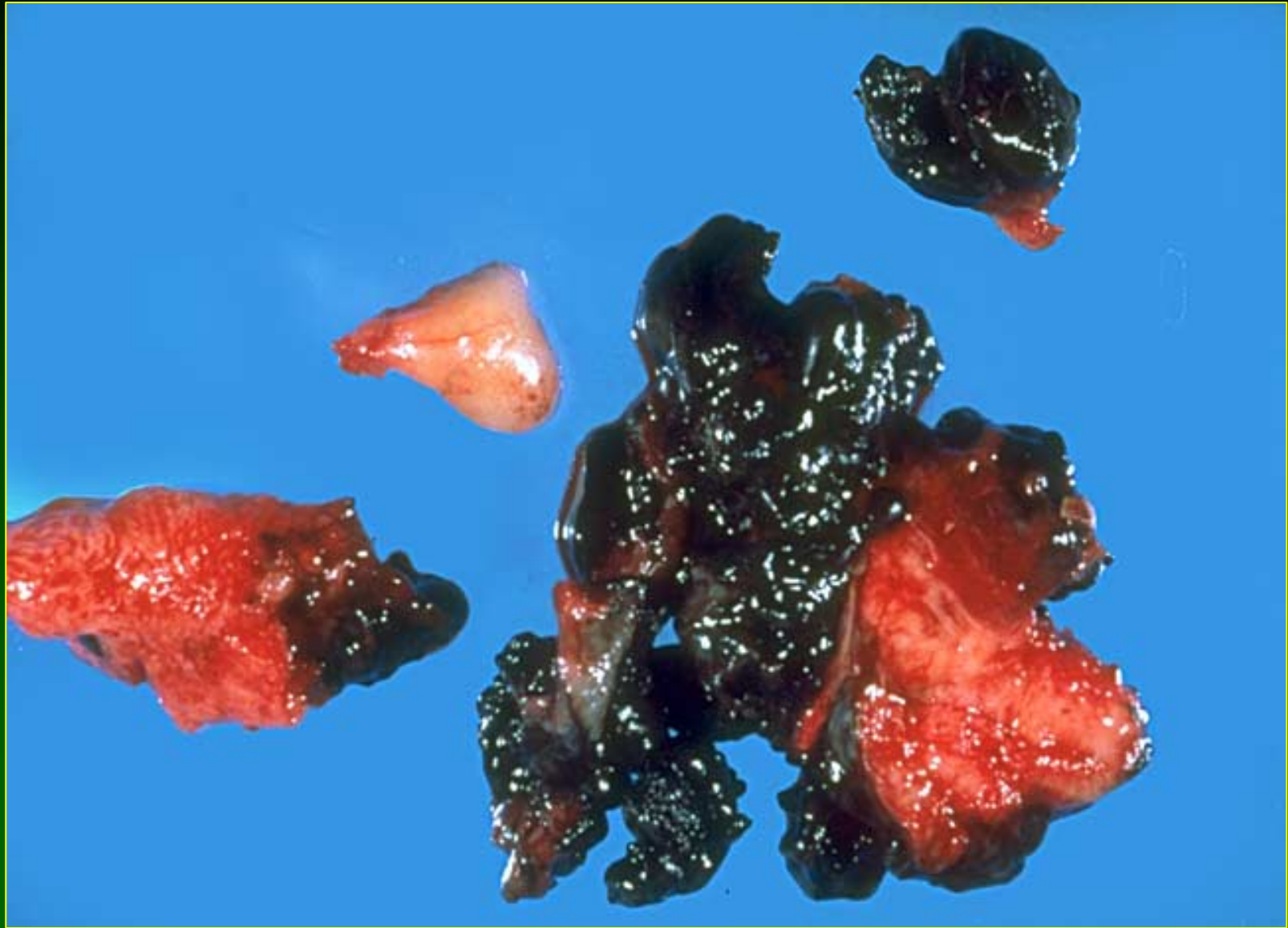Elapsed= 100 secs

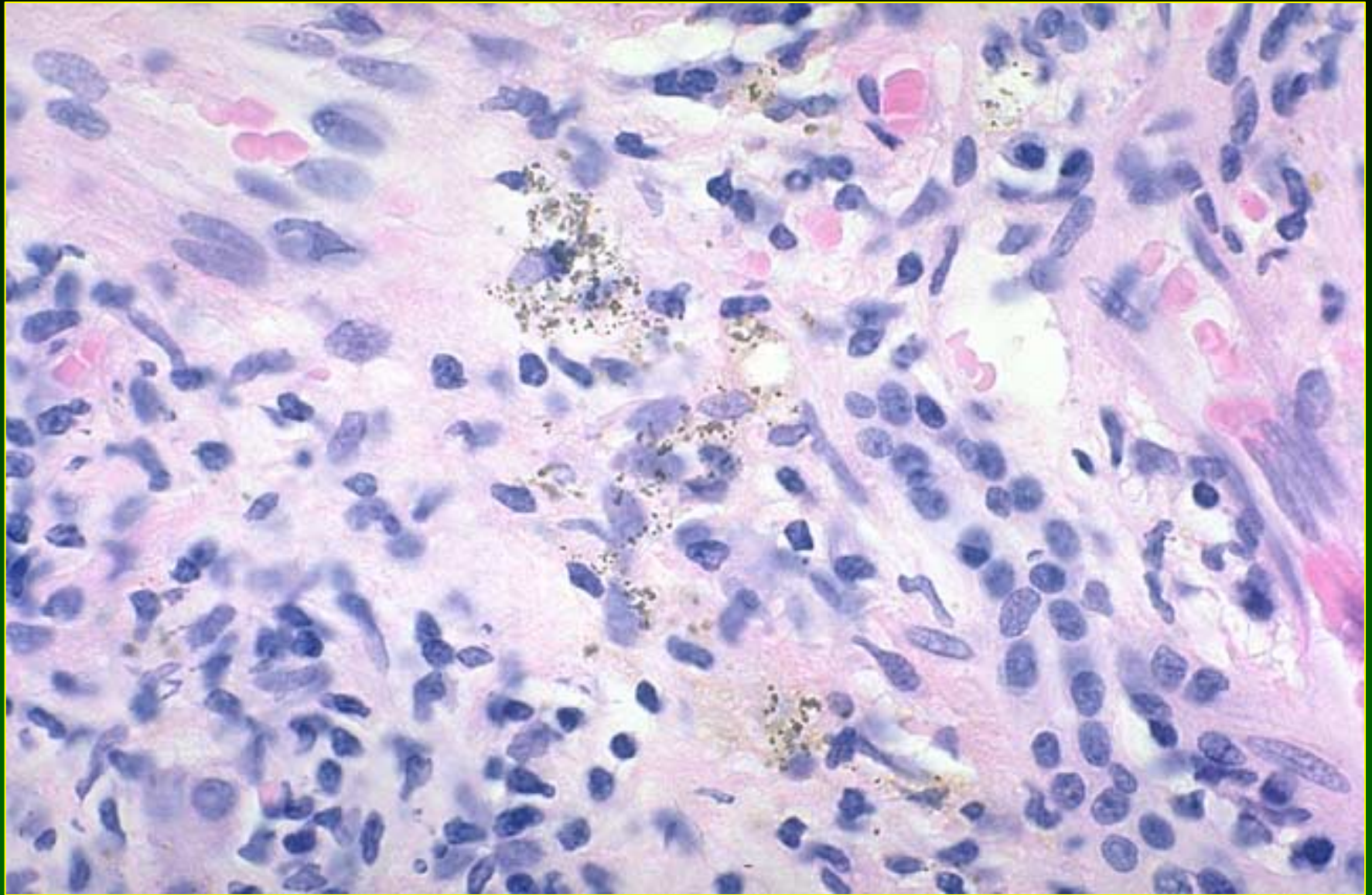


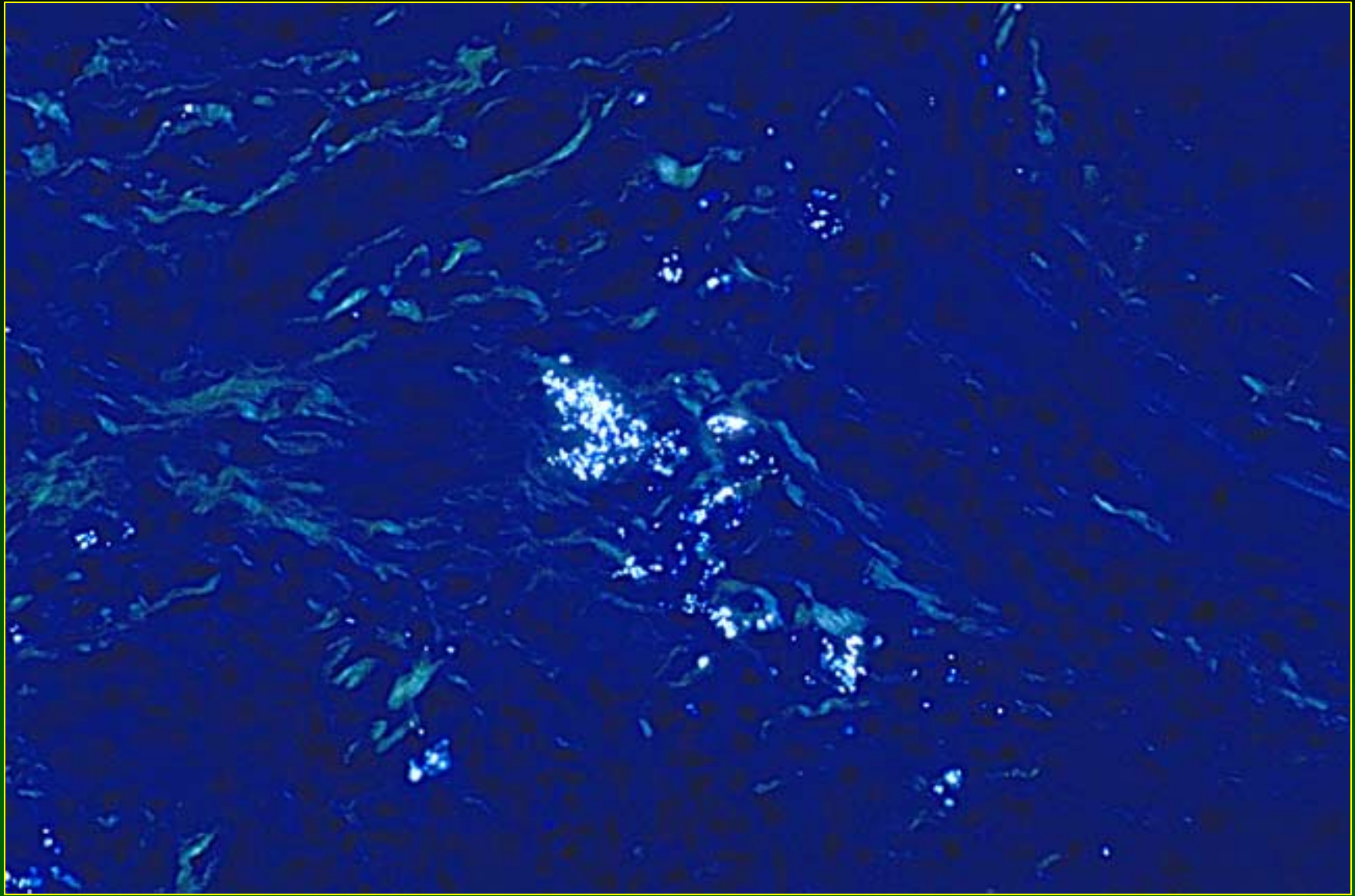
Hepatotoxicity of Metals

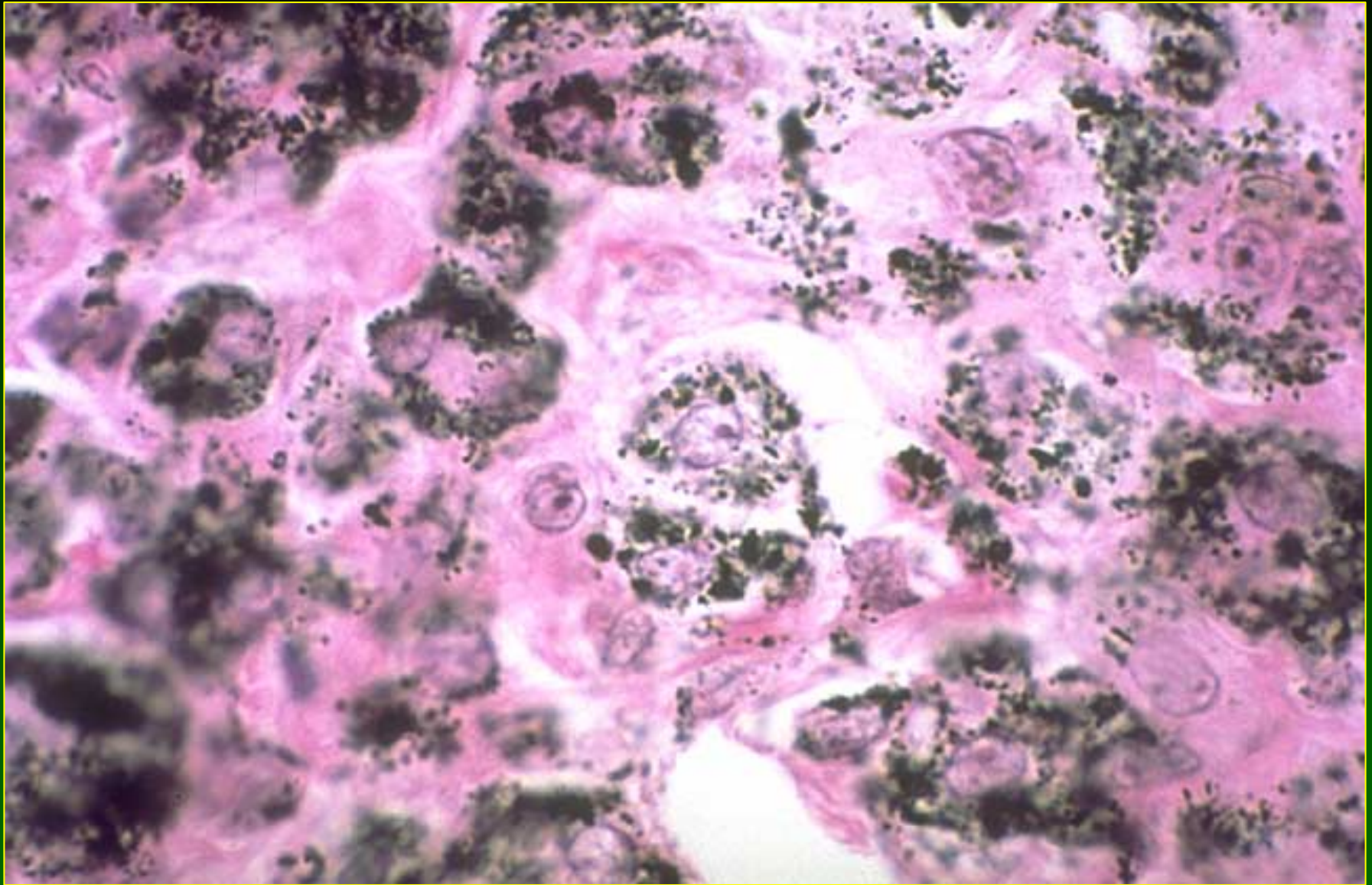
Titanium

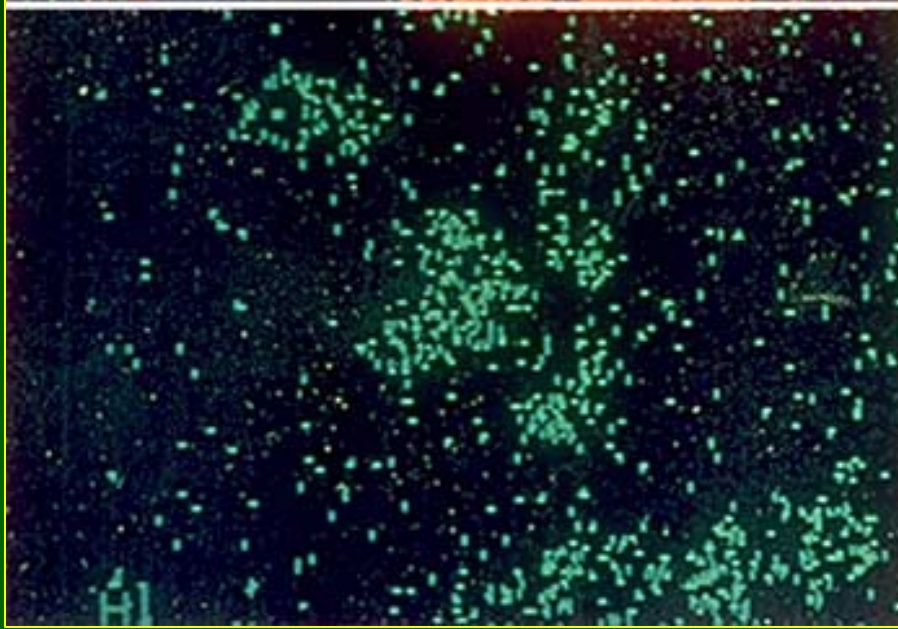
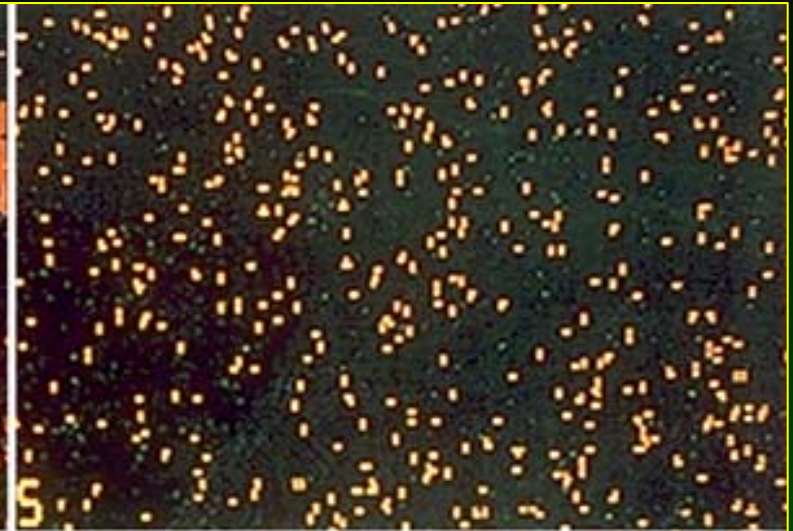
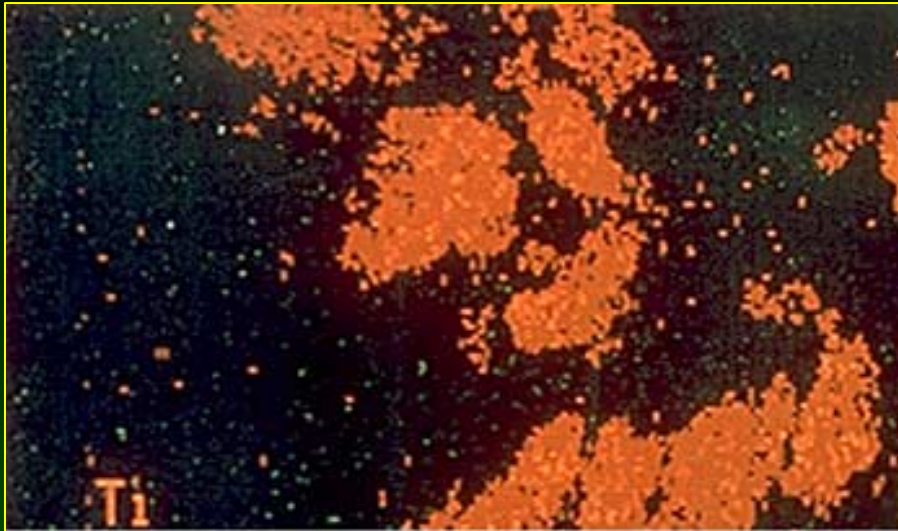
- Accumulation of black, granular pigment in Kupffer cells and portal macrophages, together with talc in Kupffer cells and portal macrophages, of intravenous abusers of drugs











14-Oct-1987 10:15:53

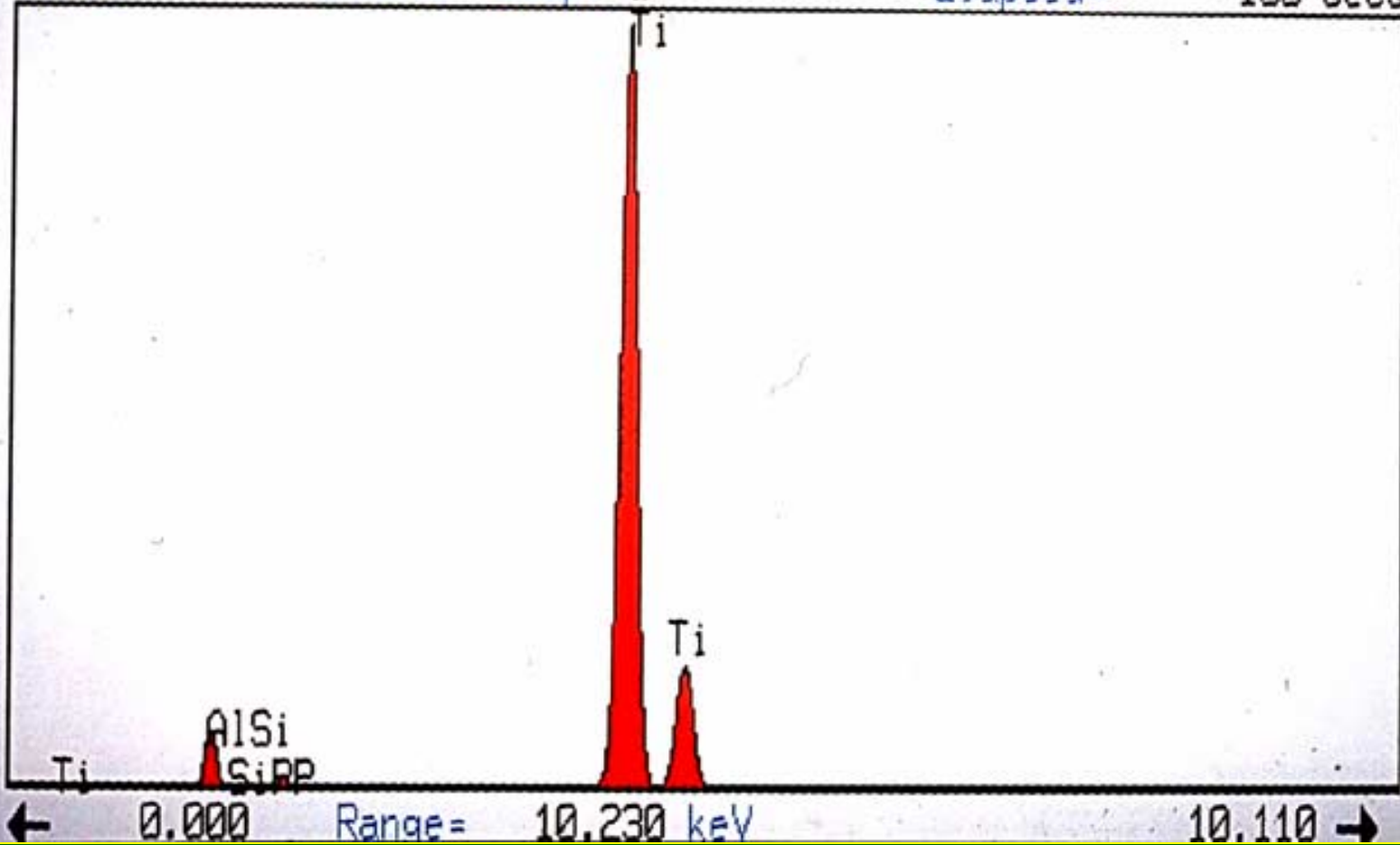
Execution time = 19 seconds

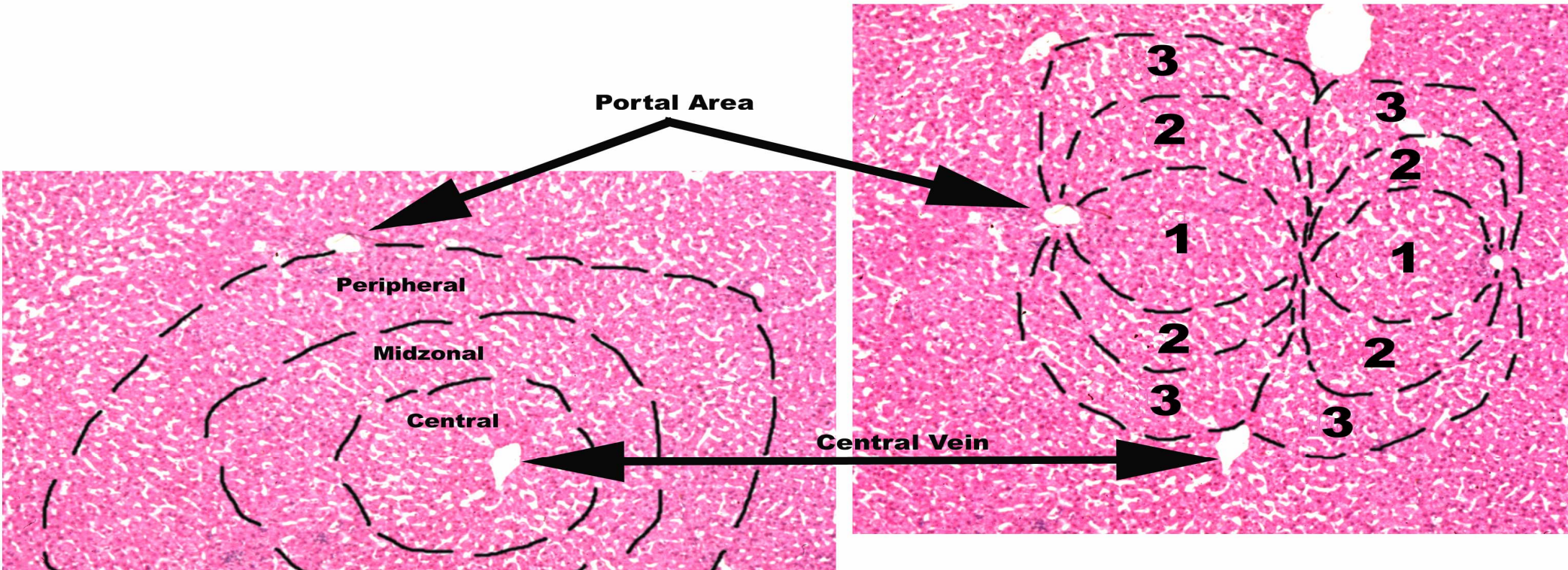
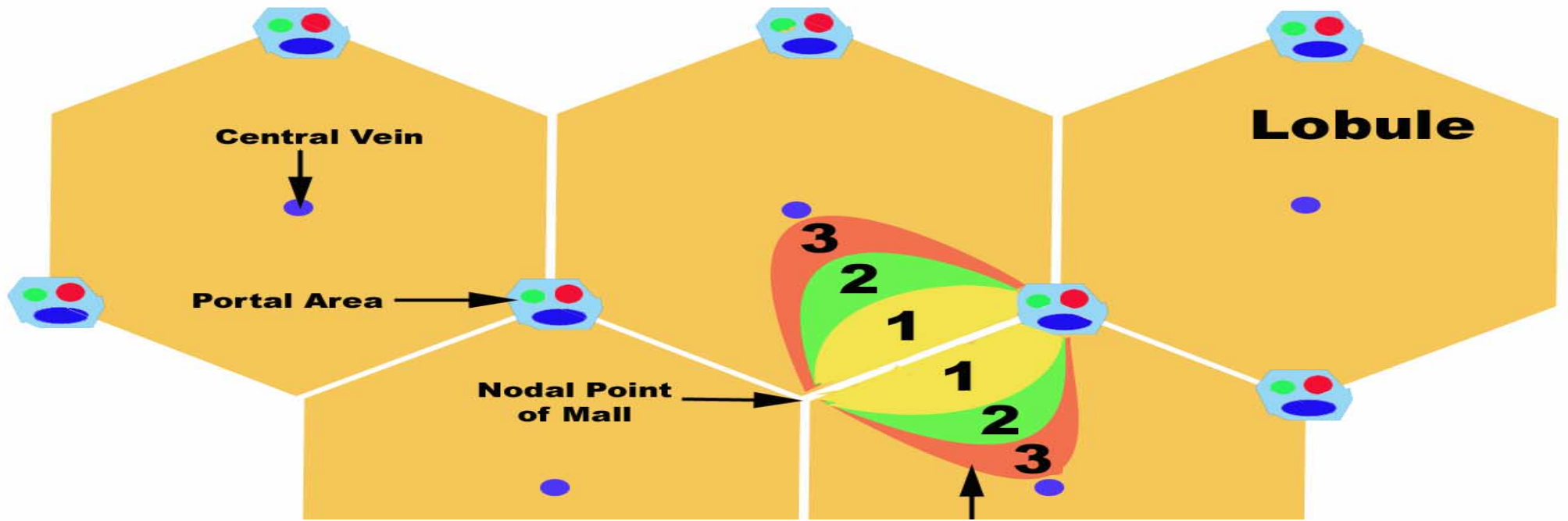
2140596

Vert= 3692 counts Disp= 1

Preset= 100 secs

Elapsed= 100 secs





Hepatotoxicity of Metals

Summary (1)

- Acute Effects:
 - Intrahepatic cholestasis
 - Submassive (e.g. zone 3 in Cu toxicity, zone 1 in phosphorus or iron toxicity)
 - Steatosis

Hepatotoxicity of Metals

Summary (2)

- Chronic Effects:
 - Granulomas
 - Fibrosis → cirrhosis
 - Vascular lesion, e.g. venoocclusive disease
 - Malignancies, e.g. angiosarcoma, cholangiocarcinoma, hepatocellular carcinoma

